

Case Report

Case Report of a Fatal *Babesia vulpes* Infection in a Splenectomised Dog

Maria Sophia Unterköfler ¹, Nikola Pantchev ², Carina Bergfeld ², Katrin Wülfig ², Majda Globokar ², Astrid Reinecke ³, Hans-Peter Fuehrer ¹ and Michael Leschnik ^{4,*}

¹ Department of Pathobiology, Institute of Parasitology, University of Veterinary Medicine Vienna, 1210 Vienna, Austria

² IDEXX Laboratories, 70806 Kornwestheim, Germany

³ Veterinary Practice Reinecke, 59872 Meschede, Germany

⁴ Clinical Unit of Internal Medicine Small Animals, Department for Companion Animals and Horses, University of Veterinary Medicine Vienna, 1210 Vienna, Austria

* Correspondence: michael.leschnik@vetmeduni.ac.at

Abstract: *Babesia vulpes* is a small *Babesia* prevalent in foxes in Europe and mainly clinically affects dogs in north-western Spain. A dog imported from this region that had been living in Germany for three years developed splenic torsion. After splenectomy, the dog underwent immunosuppressive therapy because of autoimmune disease due to haemotrophic *Mycoplasma* sp. infection. As clinical signs worsened, small *Babesia* were detected in a blood smear and identified as *B. vulpes* by molecular analysis. Anaemia, thrombocytosis, elevated liver enzymes, and renal parameters were the most significant findings in blood analysis. The dog was treated with a combination of atovaquone (20 mg/kg BW, BID), proguanil hydrochloride (8 mg/kg BW, BID) and azithromycin (10 mg/kg BW, SID), which led to an increase in the cycle threshold in real-time PCR and the absence of *B. vulpes* in the blood smear. However, after clinical signs deteriorated, the dog was euthanised. This case report supports the recommendation to screen imported dogs for pathogens and highlights the impact of splenectomy on the course of infection.

Keywords: babesiosis; piroplasmosis; *Theileria annae*; *Babesia microti*-like



Citation: Unterköfler, M.S.; Pantchev, N.; Bergfeld, C.; Wülfig, K.; Globokar, M.; Reinecke, A.; Fuehrer, H.-P.; Leschnik, M. Case Report of a Fatal *Babesia vulpes* Infection in a Splenectomised Dog. *Parasitologia* **2023**, *3*, 59–68. <https://doi.org/10.3390/parasitologia3010008>

Received: 4 January 2023

Revised: 24 January 2023

Accepted: 25 January 2023

Published: 1 February 2023



Copyright: © 2023 by the authors. Licensee MDPI, Basel, Switzerland. This article is an open access article distributed under the terms and conditions of the Creative Commons Attribution (CC BY) license (<https://creativecommons.org/licenses/by/4.0/>).

1. Introduction

Babesia spp. are primarily transmitted by hard ticks and affect the red blood cells of a broad range of hosts. In dogs, *Babesia* spp. are classified as large or small *Babesia* based on their size. In Europe, *B. canis* is the most common species in dogs. Other large *Babesia* include *B. vogeli*, which occurs in the Mediterranean region, and *B. rossi*, which has been reported from Africa and is not autochthonous in Europe. Small *Babesia* include *B. gibsoni*, which may also be transmitted by non-vector routes, *B. conradae*, which has been reported in California, and *B. vulpes* [1,2].

For *B. vulpes*, *Ixodes hexagonus* is suspected to act as vector, but transmission studies confirming this are lacking [3,4]. *Babesia vulpes* has been found in red foxes (*Vulpes vulpes*). It has a high prevalence in many countries in Europe, indicating that foxes may be the reservoirs for this parasite [4–15]. Frequent clinical cases in dogs have been reported mainly in north-western Spain, but sporadic cases have also been reported in other European countries, including Sweden, Russia, and Hungary [16–22]. Furthermore, case reports outside of Europe have been reported recently [23,24]. The first description of this parasite came from a dog that lived in Germany but travelled to north-western Spain [25].

Clinically affected dogs show fever, anorexia, apathy, severe anaemia, and haemoglobinuria due to haemolysis [16,26,27]. As with the other small *Babesia*, therapy is more complex compared to *B. canis* and often does not result in complete elimination of the pathogen. The

recommended treatment protocol is the combination of azithromycin with either atovaquone or buparvaquone [28,29].

Immunosuppression, either drug-induced or due to an underlying disease, can also complicate the course of disease in various other parasitic infections, e.g., *Toxoplasma gondii* or *Strongyloides stercoralis* [30–32]. Impaired immune defence can also be caused by splenectomy, which is known to result in higher parasitaemia and more severe clinical signs in dogs infected with *Babesia* [33–35].

Here we report a rare case of *B. vulpes* infection in a splenectomised dog imported from Spain but living in Germany for three years.

2. Results

2.1. Case History

A spayed female of unknown breed was rescued by a veterinary student from Galicia, Spain, in July 2018 and subsequently adopted by a veterinarian in Germany. At that time, the dog's age was estimated to be 10–13 years, and the dog's weight was 23–25 kg. In June 2021, the dog had to be splenectomised due to splenic torsion. The recovery was without complications. In August 2021, inappetence was noticed, and the following day the dog was apathetic and showed tachypnoea. Sonographic examination of the abdomen was unremarkable, but haematology revealed anaemia and thrombocytosis (Figure 1: 9 September 2021), and haemotrophic *Mycoplasma* spp. were detected using rt-PCR (*Mycoplasma haemocanis* (cycle threshold [Ct]: 27.18) and *Candidatus Mycoplasma haematoparvum* (Ct: 26.12)). Immune-mediated haemolytic anaemia was suspected, and the dog was treated with two blood transfusions (250 mL) from two dogs that had never travelled outside Germany. Additionally, the dog received prednisone (2 mg/kg body-weight (BW), once a day (SID), orally (p.o.), reduced to 1 mg/kg BW after 3 weeks, and stopped after two months; prednisolon—5 mg, cp-pharma, Burgdorf, Germany), doxycycline (5 mg/kg BW, twice a day (BID), p.o., for two months; Doxybactin®, Dechra, London, UK), cyclosporine (4.76 mg/kg BW, BID, p.o.; Sporimune®, Dechra, London, UK), and mycophenolate (10 mg/kg BW, BID, p.o.; Mycophenolatmofetil, Hexal, Holzkirchen, Germany). The dog clinically improved, and in October 2021, erythrocyte count was within reference limits (Figure 1: 16 October 2021), and rt-PCR for haemotrophic *Mycoplasma* spp. was negative. However, thrombocytosis was still present.

In December 2021, the condition of the dog worsened suddenly, and the dog showed haemorrhagic gastroenteritis and severe anaemia (Figure 1: 30 December 2021). Doxycycline and prednisone in the above-mentioned starting dose were once again administered additionally to cyclosporine and mycophenolate. Amoxicillin (15 mg/kg BW, s.c.; Duphomax® L.A., Zoetis, Delémont, Switzerland), metamizole (50 mg/kg BW, s.c.; Novaminsulfon, Dechra, London, UK), and maropitant (1 mg/kg BW, s.c.; VetEmex®, cp-pharma, Burgdorf, Germany) were given as supportive therapy. Two blood transfusions (250 mL) were administered, one from a dog that had never travelled outside Germany and one from a dog from Spain, which tested negative for *Babesia* spp. and *B. vulpes* by rt-PCR retrospectively, 3 weeks after application. In January 2022, a blood smear revealed the presence of small *Babesia* sp. (Figure 2), which was subsequently identified as *B. vulpes* by rt-PCR (Table 1: 6 January 2022), RFLP, and sequencing. The ELISA antibody test using *B. canis* antigen was negative at that time point. Erythrocyte count revealed marked anaemia, and liver enzymes were increased (Figure 1, Table 1: 6 January 2022). A combination compound (Malarone®, GlaxoSmithKline, London, UK) containing atovaquone (20 mg/kg BW, BID) and proguanil hydrochloride (8 mg/kg BW, BID), and azithromycin (10 mg/kg BW, SID; Zithromax®, Pfizer Cooperation GmbH; Vienna, Austria) was given p.o. for 10 days, with a one-day interruption due to severe side effects, including inappetence, vomitus, and abdominal pain. Maropitant (2 mg/kg BW, SID, p.o.; Cerenia®, Zoetis, Delémont, Switzerland) was given as supportive therapy. Cyclosporine and mycophenolate were continued, and prednisone was tapered. After two weeks, the dog's condition markedly improved. Erythrocyte counts and Ct values in rt-PCR increased (Figure 1, Table 1: 22

January 2022), pointing toward decreasing organism numbers, although the thrombocyte count was markedly elevated. Another two weeks later, the blood smear was negative for *B. vulpes* and the ELISA test for antibodies against *B. canis* antigen switched to positive (Figure 1, Table 1: 12 February 2022). Liver enzymes were still elevated but lower than before; however, creatinine and urea were increased. Clinically the dog's condition suddenly deteriorated, showing inappetence and haematochezia, and it had to be euthanised.

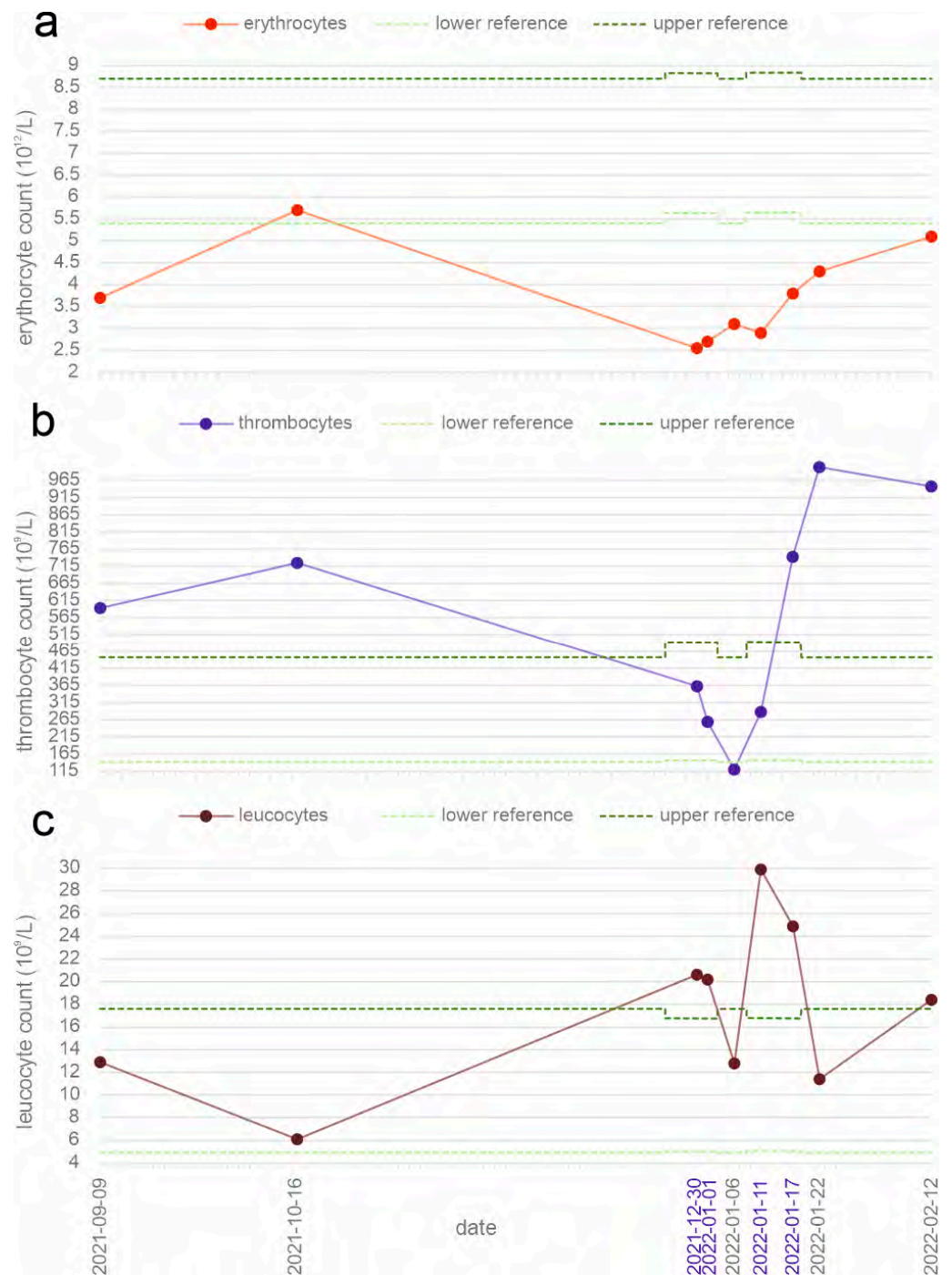


Figure 1. Erythrocyte counts (a), thrombocyte counts (b), and cell counts of leucocytes (c) at examined time points. Each point represents the measured value of each time point, and dotted lines represent reference values. Dates in blue are time points where measurement was performed with the ProCyt One[®] Haematology Analyser (IDEXX, Vienna, Austria).

Table 1. Results of cycle threshold (Ct) value of *B. vulpes* rt-PCR, test result (TR) value of ELISA antibody test, liver enzymes, creatinine, and urea from the blood analysis of three different time points.

	6 January 2022	22 January 2022	12 February 2022	Reference
rt-PCR <i>B. vulpes</i> (Ct value)	14.18	19.14	26.1	<40: positive <14: negative; 14–19: borderline; >19: positive
ELISA <i>B. canis</i> (TR value)	12.3		32	25–122
alanine transaminase (U/L)	1 086		589	14–59
aspartate transaminase (U/L)	128		37	14–147
alkaline phosphatase (U/L)	3 435		2 466	2–13
gamma-glutamyltransferase (U/L)	306		177	1–18
glutamate dehydrogenase (U/L)	70		46	0–6.84
total bilirubin (μmol/L)	39.33		11.97	44.2–132.6
creatinine (μmol/L)	35.36		194.48	3.21–10.35
urea (mmol/L)	8.21		13.57	

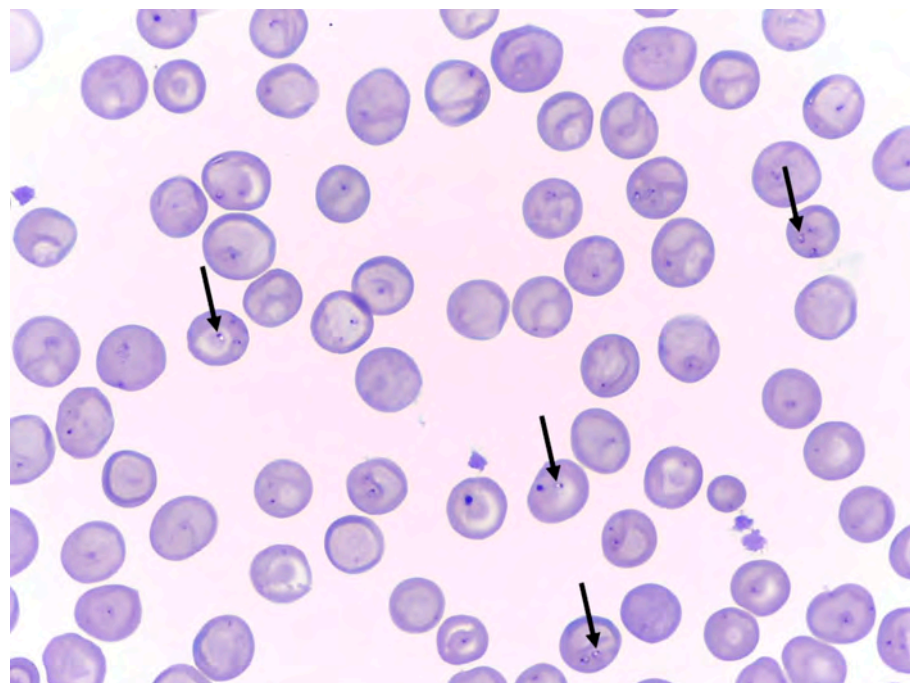


Figure 2. Diff-Quick stained peripheral blood smear before treatment against *Babesia vulpes*. Black arrows indicate *B. vulpes*.

2.2. Molecular Analysis

The rt-PCR was negative for several *Babesia* spp. (*B. canis*, *B. vogeli*, *B. rossi*, *B. gibsoni*, and *B. conradae*) but positive for *B. vulpes* at the three time points examined as the Ct value increased (Table 1). PCR-RFLP showed fragments of around 485, 139, and 111 bp (HinfI); and 452, 192, and 146 bp (TaqI) in length, which is expected for *B. vulpes* (Figure 3). Sequencing of an 801 bp long 18S rRNA gene fragment showed 100% identity to *B. vulpes* found in a red fox (*Vulpes vulpes*) from Spain (GenBank accession number: KT223483). The obtained sequence was deposited in GenBank (accession number: ON968708).

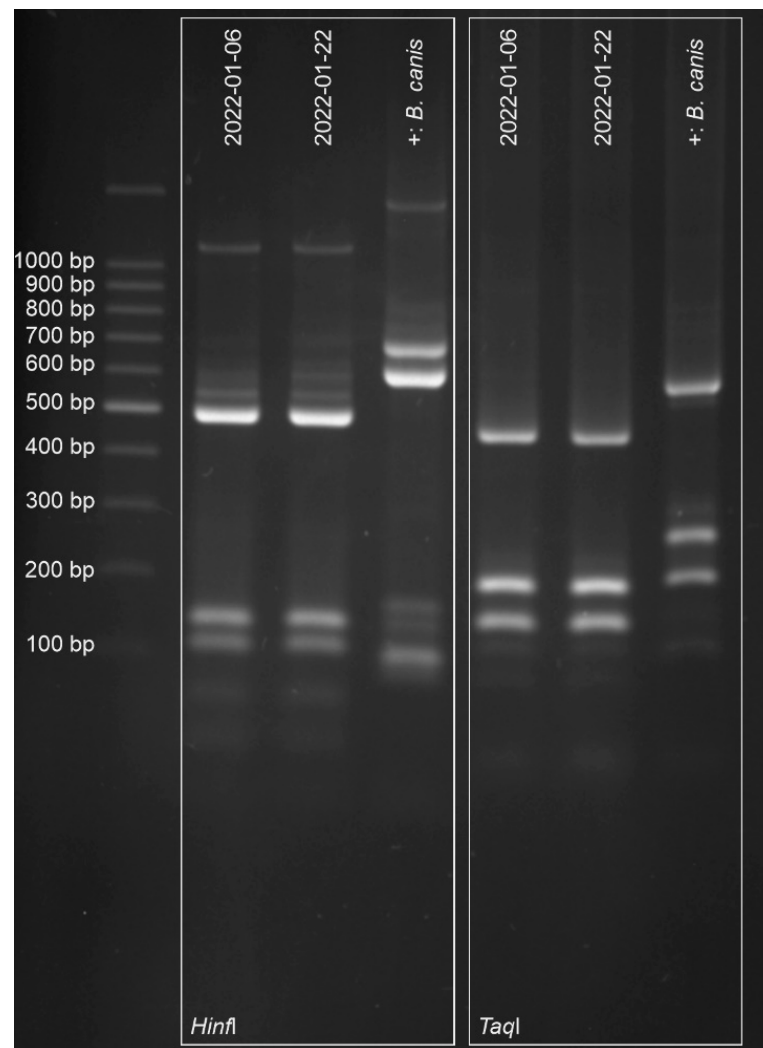


Figure 3. Gel electrophoresis of PCR-RFLP 18S rRNA gene fragments. Lane 1 presents a 100 bp molecular weight marker, lanes 2 to 4 and lanes 5 to 7 present PCR-RFLP products digested with endonucleases *Hinfi* and *TaqI*, respectively. Lanes 2, 3, 5, and 6 present samples of the patient from two different time points, and lanes 4 and 7 present a sample with *B. canis* as positive controls.

3. Discussion

As in other cases of splenectomised dogs with *Babesia* infection, the present case showed severe clinical signs and eventually had to be euthanised [34,36]. Cases of splenectomised dogs with *B. canis*, *B. vogeli*, and *B. gibsoni* infection have been reported [1,33–37], and even a case report of *B. vulpes* is present in the literature [1]. Furthermore, another similar case has recently been published from Germany, which represents the first putative autochthonous *B. vulpes* infection in Germany in a dog [38]. According to the dog's owners, the eleven-year-old dog had never left the country except for a holiday visit to Denmark. In this case, the positive PCR for *Babesia* sp. was initially interpreted as *B. canis* infection, and only subsequent sequencing revealed that it was *B. vulpes*. However, neither an entry in GenBank, nor details on the amplified gene fragment, are available. Moreover, the origin and travel history rely solely on the information provided by the owner, so an autochthonous infection in Germany cannot be considered as confirmed [38].

Similarly to the present case, Tuttle et al. [39] reported a *B. canis* infection in a dog, which became clinically apparent after the dog was treated for 5 months with immunosuppressive therapy for a *Bartonella vinsonii* infection. In the present case, no retrospective detection of the pathogen was possible, as there were no archived samples available. Although foxes in Germany were found to be positive for *B. vulpes*, this dog most likely acquired the infection in north-western Spain, where most clinical cases in dogs are reported [14–16]. The dog was living in Germany for three years without showing clinical signs of infection; however, splenectomy and immunosuppressive drugs given for the treatment of suspected immune-mediated haemolytic anaemia probably led to the unrestrained proliferation of *B. vulpes* and subsequent clinical disease [33,35,36]. It is not clear why *B. vulpes* has a high prevalence in foxes in many European countries, but cases rarely occur in dogs outside north-western Spain. Differences in vector distribution or density of fox population might contribute to this [4,40]. *Ixodes hexagonus* is considered a likely candidate as a vector, and indeed, differences in the distribution are present [3,4]. In north-western Spain, 38.5% of ticks found on dogs were *I. hexagonus* [40]. In Germany, *I. hexagonus* is mainly found in foxes and hedgehogs (*Erinaceus europaeus*, *E. roumanicus*), but cases of dogs being infested have been reported [41,42]. Surveys on ticks collected from dogs revealed 1.2% of them are *I. hexagonus* in Switzerland, 0.4% are in Austria, and 8.8% are in north-eastern Germany [43–45]. Although present in both regions, the prevalence of dogs infested with *I. hexagonus* is significantly higher in north-western Spain. *Ixodes hexagonus* is found on nearly 40% of the dogs there, and *B. vulpes* is the predominant *Babesia* species in dogs in north-western Spain. In other regions, lower infestation rates with *I. hexagonus* and rare autochthonous cases of *B. vulpes* infection in dogs are reported. These observations support the hypothesis that *I. hexagonus* could be the vector [40]. However, the vector competence of this tick vector has to be confirmed in further studies. Which other factors contribute to the high infestation rates with *I. hexagonus* and *B. vulpes* among dogs in Spain, in contrast to other regions (including habitat, climate, wildlife reservoir, lifestyle of dogs, among others), should also be further investigated. Other transmission routes should also be evaluated in further studies.

Nevertheless, it seems theoretically possible to acquire infection with *B. vulpes* in Germany if contact with an infected vector should occur. Moreover, imported infections can lead to clinical disease even years later, if an event that favours parasite multiplication, such as splenectomy, occurs [14,15,36,38].

Thrombocytopenia is a common feature in infections with *B. vulpes*; however, this case showed marked thrombocytosis [16,20]. Splenectomy can result in thrombocytosis in dogs, but platelet counts usually return to normal levels within a few weeks after surgery [46,47]. Presumably, thrombocytosis was due to glucocorticoid treatment, as might also be the case for leucocytosis [48,49]. However, leucocytosis was markedly present when measured with the ProCyte One® Haematology Analyser. Whether this was true leucocytosis at that time point, and there was no marked leucocytosis at the other time points, or if the differences were due to the different machines that were used could not be conclusively clarified, because no blood samples were tested with both devices at the same time point.

Even though the laboratory findings were suggestive of an improvement of the infection, seen by the increase in the Ct value and the absence of organisms in blood smear, the dog had to be euthanised because clinical signs deteriorated. The damage to the liver and kidneys might have been too severe at that stage. This damage may be a sequela of haemolysis and could have been exacerbated by drug treatment [50,51]. Kidney disease is a common complication in infections with *Babesia*, and azotaemia was found to be significantly associated with death in dogs with *B. vulpes* infection [20,26,37].

4. Materials and Methods

At IDEXX Laboratories, blood smear, complete blood count, biochemistry panel, serological testing, and real-time PCR (rt-PCR) were performed. Complete blood count in clinic was performed with the ProCyt One[®] Haematology Analyser (IDEXX, Vienna, Austria), and a biochemistry panel was examined with the Catalyst One[®] Chemistry Analyser (IDEXX, Vienna, Austria). Serological testing was performed with an enzyme-linked immunosorbent assay (ELISA) test (Babesia-ELISA Dog, AFOSA GmbH, Berlin, Germany), detecting IgG antibodies according to the manufacturer's instructions [52]. The rt-PCR was performed with a Qube MDx real-time analyser as described previously by Strobl et al. [53], with the following modification for *B. vulpes*: target gene was cytochrome c oxidase subunit I gene, and for haemotrophic mycoplasma (*Mycoplasma haemocanis* and *Candidatus Mycoplasma haematoparvum*), the 16S ribosomal RNA gene.

At the University of Veterinary Medicine Vienna, a combination of PCR and restriction fragment length polymorphism (PCR-RFLP) was adapted from the protocol described by René-Martellet et al. [54]. Briefly, nested PCR targeting a fragment of the 18S rRNA gene was performed using external primers BTF1/BTR1 and internal primers BTF2/BTR2 [55]. Adaptions were made to the reaction mixture, which contained 5 µL extracted DNA, 2 µL forward and reverse primers (10 pmol/µL), 0.25 µL Taq polymerase (5 u/µL, GoTaq[®] G2 DNA Polymerase, Promega, Madison, WI, USA), 0.4 µL deoxyribonucleotides (25 mM), 10 µL reaction buffer, and 30.35 µL nuclease free water; and to the reaction temperature profile, which was 2 min at 94 °C for initial denaturation, followed by 40 cycles in the primary reaction or 35 cycles in the secondary reaction of 45 sec at 94 °C; 45 sec at 52 °C in the primary reaction or 62 °C in secondary reaction; 1 min at 72 °C; and 5 min at 72 °C as a final extension. PCR products were subsequently digested with the restriction enzymes HinfI and TaqI for RFLP and visualised by agarose gel electrophoresis. For Sanger sequencing, PCR products were sent to LGC Genomics and after aligning and trimming the primer-binding regions compared to GenBank entries using the blastn function.

5. Conclusions

Even in countries where clinical cases in dogs are still rare, *B. vulpes* should be added to the list of differential diagnoses if clinical signs are present, and imported dogs from endemic areas should be screened for relevant pathogens. Especially in splenectomised dogs, clinical signs caused by *B. vulpes* might recur, possibly enhanced by haemotrophic *Mycoplasma* spp. co-infections, and can result in a fatal outcome.

Author Contributions: Conceptualization, M.S.U., M.L., H.-P.F. and N.P.; methodology, M.S.U., M.L., H.-P.F. and N.P.; formal analysis, M.S.U., M.L., H.-P.F. and N.P.; investigation, M.S.U., N.P., C.B., K.W., M.G., A.R., H.-P.F. and M.L.; resources, H.-P.F. and N.P.; data curation, M.S.U., N.P., C.B., K.W., M.G., A.R. and H.-P.F.; writing—original draft preparation, M.S.U.; writing—review and editing, M.L. and N.P.; visualization, M.S.U., N.P., C.B., K.W. and M.G.; supervision, M.L. and H.-P.F. All authors have read and agreed to the published version of the manuscript.

Funding: This research received no external funding.

Institutional Review Board Statement: Ethical review and approval were waived for this study due to the circumstance that it is a case report where the samples were taken for medical reasons.

Informed Consent Statement: Not applicable.

Data Availability Statement: Additional data can be provided on request.

Acknowledgments: The authors would like to thank Bitu Shahi-Barogh and Licha N. Wortha for their help with the laboratory work.

Conflicts of Interest: The authors declare no conflict of interest.

References

- Solano-Gallego, L.; Sainz, Á.; Roura, X.; Estrada-Peña, A.; Miró, G. A review of canine babesiosis: The European perspective. *Parasit. Vectors* **2016**, *9*, 336. [\[CrossRef\]](#) [\[PubMed\]](#)
- Baneth, G.; Cardoso, L.; Brilhante-Simões, P.; Schnittger, L. Establishment of *Babesia vulpes* n. sp. (Apicomplexa: Babesiidae), a piroplasmid species pathogenic for domestic dogs. *Parasit. Vectors* **2019**, *12*, 129. [\[CrossRef\]](#) [\[PubMed\]](#)
- Camacho, A.T.; Pallas, E.; Gestal, J.J.; Guitián, F.J.; Olmeda, A.S.; Telford, S.R.; Spielman, A. *Ixodes hexagonus* is the main candidate as vector of *Theileria annae* in northwest Spain. *Vet. Parasitol.* **2003**, *112*, 157–163. [\[CrossRef\]](#)
- Checa, R.; López-Beceiro, A.M.; Montoya, A.; Barrera, J.P.; Ortega, N.; Gálvez, R.; Marino, V.; González, J.; Olmeda, Á.S.; Fidalgo, L.E.; et al. *Babesia microti*-like piroplasm (syn. *Babesia vulpes*) infection in red foxes (*Vulpes vulpes*) in NW Spain (Galicia) and its relationship with *Ixodes hexagonus*. *Vet. Parasitol.* **2018**, *252*, 22–28. [\[CrossRef\]](#) [\[PubMed\]](#)
- Bartley, P.M.; Hamilton, C.; Wilson, C.; Innes, E.A.; Katzer, F. Detection of *Babesia annae* DNA in lung exudate samples from Red foxes (*Vulpes vulpes*) in Great Britain. *Parasit. Vectors* **2016**, *9*, 84. [\[CrossRef\]](#) [\[PubMed\]](#)
- Mierzejewska, E.J.; Dwuznik, D.; Koczwarska, J.; Stańczak, L.; Opalińska, P.; Krokowska-Paluszak, M.; Wierzbicka, A.; Górecki, G.; Bajer, A. The red fox (*Vulpes vulpes*), a possible reservoir of *Babesia vulpes*, *B. canis* and *Hepatozoon canis* and its association with the tick *Dermacentor reticulatus* occurrence. *Ticks Tick Borne Dis.* **2021**, *12*, 101551. [\[CrossRef\]](#)
- Santoro, M.; Auriemma, C.; Lucibelli, M.G.; Borriello, G.; D'Alessio, N.; Sgroi, G.; Veneziano, V.; Galiero, G.; Fusco, G. Molecular Detection of *Babesia* spp. (Apicomplexa: Piroplasma) in Free-Ranging Canids and Mustelids from Southern Italy. *Front. Vet. Sci.* **2019**, *6*, 269. [\[CrossRef\]](#)
- Battisti, E.; Zanet, S.; Khalili, S.; Trisciuglio, A.; Hertel, B.; Ferroglio, E. Molecular Survey on Vector-Borne Pathogens in Alpine Wild Carnivorans. *Front. Vet. Sci.* **2020**, *7*, 1. [\[CrossRef\]](#)
- Duscher, G.G.; Fuehrer, H.-P.; Kübber-Heiss, A. Fox on the run—Molecular surveillance of fox blood and tissue for the occurrence of tick-borne pathogens in Austria. *Parasit. Vectors* **2014**, *7*, 521. [\[CrossRef\]](#)
- Hodžić, A.; Mrowietz, N.; Cézanne, R.; Bruckschwaiger, P.; Punz, S.; Habler, V.E.; Tomsik, V.; Lazar, J.; Duscher, G.G.; Glawischnig, W.; et al. Occurrence and diversity of arthropod-transmitted pathogens in red foxes (*Vulpes vulpes*) in western Austria, and possible vertical (transplacental) transmission of *Hepatozoon canis*. *Parasitology* **2018**, *145*, 335–344. [\[CrossRef\]](#)
- Cardoso, L.; Cortes, H.C.E.; Reis, A.; Rodrigues, P.; Simões, M.; Lopes, A.P.; Vila-Viçosa, M.J.; Talmi-Frank, D.; Eyal, O.; Solano-Gallego, L.; et al. Prevalence of *Babesia microti*-like infection in red foxes (*Vulpes vulpes*) from Portugal. *Vet. Parasitol.* **2013**, *196*, 90–95. [\[CrossRef\]](#)
- Koneval, M.; Miterpáková, M.; Hurníková, Z.; Blaňarová, L.; Vichová, B. Neglected intravascular pathogens, *Babesia vulpes* and haemotropic *Mycoplasma* spp. in European red fox (*Vulpes vulpes*) population. *Vet. Parasitol.* **2017**, *243*, 176–182. [\[CrossRef\]](#) [\[PubMed\]](#)
- Dezdek, D.; Vojšta, L.; Curković, S.; Lipej, Z.; Mihaljević, Z.; Cvetnić, Z.; Beck, R. Molecular detection of *Theileria annae* and *Hepatozoon canis* in foxes (*Vulpes vulpes*) in Croatia. *Vet. Parasitol.* **2010**, *172*, 333–336. [\[CrossRef\]](#) [\[PubMed\]](#)
- Liesner, J.M.; Krücken, J.; Schaper, R.; Pachnicke, S.; Kohn, B.; Müller, E.; Schulze, C.; Samson-Himmelstjerna, G. von. Vector-borne pathogens in dogs and red foxes from the federal state of Brandenburg, Germany. *Vet. Parasitol.* **2016**, *224*, 44–51. [\[CrossRef\]](#) [\[PubMed\]](#)
- Najm, N.-A.; Meyer-Kayser, E.; Hoffmann, L.; Herb, I.; Fensterer, V.; Pfister, K.; Silaghi, C. A molecular survey of *Babesia* spp. and *Theileria* spp. in red foxes (*Vulpes vulpes*) and their ticks from Thuringia, Germany. *Ticks Tick Borne Dis.* **2014**, *5*, 386–391. [\[CrossRef\]](#)
- Miró, G.; Checa, R.; Paparini, A.; Ortega, N.; González-Fraga, J.L.; Gofton, A.; Bartolomé, A.; Montoya, A.; Gálvez, R.; Mayo, P.P.; et al. *Theileria annae* (syn. *Babesia microti*-like) infection in dogs in NW Spain detected using direct and indirect diagnostic techniques: Clinical report of 75 cases. *Parasit. Vectors* **2015**, *8*, 217. [\[CrossRef\]](#)
- Falkenö, U.; Tasker, S.; Osterman-Lind, E.; Tvedten, H.W. *Theileria annae* in a young Swedish dog. *Acta Vet. Scand.* **2013**, *55*, 50. [\[CrossRef\]](#)
- Radyuk, E.; Karan, L. A case of *Babesia vulpes* infection in a dog in Russia. *Vet. Parasitol. Reg. Stud. Rep.* **2020**, *22*, 100467. [\[CrossRef\]](#)
- Tuska-Szalay, B.; Vizi, Z.; Hofmann-Lehmann, R.; Vajdovich, P.; Takács, N.; Meli, M.L.; Farkas, R.; Stummer-Knyihár, V.; Jerzsele, Á.; Kontschán, J.; et al. *Babesia gibsoni* emerging with high prevalence and co-infections in “fighting dogs” in Hungary. *Curr. Res. Parasitol. Vector Borne Dis.* **2021**, *1*, 100048. [\[CrossRef\]](#)
- Camacho, A.T.; Pallas, E.; Gestal, J.J.; Guitián, F.J.; Olmeda, A.S.; Goethert, H.K.; Telford, S.R. Infection of dogs in north-west Spain with a *Babesia microti*-like agent. *Vet. Rec.* **2001**, *149*, 552–555. [\[CrossRef\]](#)
- Yisaschar-Mekuzas, Y.; Jaffe, C.L.; Pastor, J.; Cardoso, L.; Baneth, G. Identification of *Babesia* species infecting dogs using reverse line blot hybridization for six canine piroplasms, and evaluation of co-infection by other vector-borne pathogens. *Vet. Parasitol.* **2013**, *191*, 367–373. [\[CrossRef\]](#) [\[PubMed\]](#)
- Simões, P.B.; Cardoso, L.; Araújo, M.; Yisaschar-Mekuzas, Y.; Baneth, G. Babesiosis due to the canine *Babesia microti*-like small piroplasm in dogs—first report from Portugal and possible vertical transmission. *Parasit. Vectors* **2011**, *4*, 50. [\[CrossRef\]](#)
- Barash, N.R.; Thomas, B.; Birkenheuer, A.J.; Breitschwerdt, E.B.; Lemler, E.; Qurollo, B.A. Prevalence of *Babesia* spp. and clinical characteristics of *Babesia vulpes* infections in North American dogs. *J. Vet. Intern. Med.* **2019**, *33*, 2075–2081. [\[CrossRef\]](#) [\[PubMed\]](#)
- Arsenault, A.C.; Foley, P.M.; Clancey, N.P. *Babesia vulpes* in a dog from Prince Edward Island, Canada. *Can. Vet. J.* **2022**, *63*, 589–592. [\[PubMed\]](#)
- Zahler, M.; Rinder, H.; Schein, E.; Gothe, R. Detection of a new pathogenic *Babesia microti*-like species in dogs. *Vet. Parasitol.* **2000**, *89*, 241–248. [\[CrossRef\]](#)

26. Camacho, A.T.; Guitián, F.J.; Pallas, E.; Gestal, J.J.; Olmeda, A.S.; Goethert, H.K.; Telford, S.R.; Spielman, A. Azotemia and Mortality among *Babesia microti*-Like Infected Dogs. *J. Vet. Intern. Med.* **2004**, *18*, 141. [\[CrossRef\]](#)
27. Guitián, F.J.; Camacho, A.T.; Telford, S.R. Case-control study of canine infection by a newly recognised *Babesia microti*-like piroplasm. *Prev. Vet. Med.* **2003**, *61*, 137–145. [\[CrossRef\]](#) [\[PubMed\]](#)
28. Baneth, G. Antiprotozoal treatment of canine babesiosis. *Vet. Parasitol.* **2018**, *254*, 58–63. [\[CrossRef\]](#) [\[PubMed\]](#)
29. Checa, R.; Montoya, A.; Ortega, N.; González-Fraga, J.L.; Bartolomé, A.; Gálvez, R.; Marino, V.; Miró, G. Efficacy, safety and tolerance of imidocarb dipropionate versus atovaquone or buparvaquone plus azithromycin used to treat sick dogs naturally infected with the *Babesia microti*-like piroplasm. *Parasit. Vectors* **2017**, *10*, 145. [\[CrossRef\]](#)
30. Paradies, P.; Iarussi, F.; Sasanelli, M.; Capogna, A.; Lia, R.P.; Zucca, D.; Greco, B.; Cantacessi, C.; Otranto, D. Occurrence of strongyloidiasis in privately owned and sheltered dogs: Clinical presentation and treatment outcome. *Parasit. Vectors* **2017**, *10*, 345. [\[CrossRef\]](#)
31. Dubey, J.P.; Murata, F.H.A.; Cerqueira-Cézar, C.K.; Kwok, O.C.H.; Yang, Y.; Su, C. *Toxoplasma gondii* infections in dogs: 2009–2020. *Vet. Parasitol.* **2020**, *287*, 109223. [\[CrossRef\]](#) [\[PubMed\]](#)
32. Chappell, L.H.; Wastling, J.M. Cyclosporin A: Antiparasite drug, modulator of the host-parasite relationship and immunosuppressant. *Parasitology* **1992**, *105*, S25–S40. [\[CrossRef\]](#) [\[PubMed\]](#)
33. Máthé, A.; Vörös, K.; Németh, T.; Biksi, I.; Hettyey, C.; Manczur, F.; Tekes, L. Clinicopathological changes and effect of imidocarb therapy in dogs experimentally infected with *Babesia canis*. *Acta Vet. Hung.* **2006**, *54*, 19–33. [\[CrossRef\]](#) [\[PubMed\]](#)
34. Camacho, A.T.; Pallas, E.; Gestal, J.J.; Guitián, F.J.; Olmeda, A.S. *Babesia canis* infection in a splenectomized dog. *Bull. Soc. Pathol. Exot.* **2001**, *94*, 17–19.
35. Sikorski, L.E.; Birkenheuer, A.J.; Holowaychuk, M.K.; McCleary-Wheeler, A.L.; Davis, J.M.; Littman, M.P. Babesiosis caused by a large *Babesia* species in 7 immunocompromised dogs. *J. Vet. Intern. Med.* **2010**, *24*, 127–131. [\[CrossRef\]](#)
36. Trotta, M.; Carli, E.; Novari, G.; Furlanello, T.; Solano-Gallego, L. Clinicopathological findings, molecular detection and characterization of *Babesia gibsoni* infection in a sick dog from Italy. *Vet. Parasitol.* **2009**, *165*, 318–322. [\[CrossRef\]](#)
37. Wozniak, E.J.; Barr, B.C.; Thomford, J.W.; Yamane, I.; McDonough, S.P.; Moore, P.F.; Naydan, D.; Robinson, T.W.; Conrad, P.A. Clinical, Anatomic, and Immunopathologic Characterization of *Babesia gibsoni* Infection in the Domestic Dog (*Canis familiaris*). *J. Parasitol.* **1997**, *83*, 692. [\[CrossRef\]](#)
38. Jetschin, S.; Bitter, V.; Neiger, R. *Babesia vulpes*-Infektion bei einem Hund in Deutschland—Mögliche Übertragungswege. *Kleintierpraxis* **2022**, *67*, 250–258. [\[CrossRef\]](#)
39. Tuttle, A.D.; Birkenheuer, A.J.; Juopperi, T.; Levy, M.G.; Breitschwerdt, E.B. Concurrent bartonellosis and babesiosis in a dog with persistent thrombocytopenia. *J. Am. Vet. Med. Assoc.* **2003**, *223*, 1306–1310. [\[CrossRef\]](#)
40. Checa, R.; Fidalgo, L.E.; Montoya, A.; López, A.M.; Barrera, J.P.; Gálvez, R.; La Sánchez de Nieta, S.; Marino, V.; Sarquis, J.; Miró, G. The role of healthy dog carriers of *Babesia microti*-like piroplasms. *Parasit. Vectors* **2019**, *12*, 127. [\[CrossRef\]](#)
41. Kahl, O.; Bulling, I.; Chitimia-Dobler, L. Some new findings on the endophilic vector tick *Ixodes hexagonus* in Germany. *Ticks Tick Borne Dis.* **2022**, *13*, 101954. [\[CrossRef\]](#) [\[PubMed\]](#)
42. Rubel, F.; Brugger, K.; Chitimia-Dobler, L.; Dautel, H.; Meyer-Kayser, E.; Kahl, O. Atlas of ticks (Acari: Argasidae, Ixodidae) in Germany. *Exp. Appl. Acarol.* **2021**, *84*, 183–214. [\[CrossRef\]](#) [\[PubMed\]](#)
43. Duscher, G.G.; Feiler, A.; Leschnik, M.; Joachim, A. Seasonal and spatial distribution of ixodid tick species feeding on naturally infested dogs from Eastern Austria and the influence of acaricides/repellents on these parameters. *Parasit. Vectors* **2013**, *6*, 76. [\[CrossRef\]](#) [\[PubMed\]](#)
44. Eichenberger, R.M.; Deplazes, P.; Mathis, A. Ticks on dogs and cats: A pet owner-based survey in a rural town in northeastern Switzerland. *Ticks Tick Borne Dis.* **2015**, *6*, 267–271. [\[CrossRef\]](#) [\[PubMed\]](#)
45. Beck, S.; Schreiber, C.; Schein, E.; Krücken, J.; Baldermann, C.; Pachnicke, S.; von Samson-Himmelstjerna, G.; Kohn, B. Tick infestation and prophylaxis of dogs in northeastern Germany: A prospective study. *Ticks Tick Borne Dis.* **2014**, *5*, 336–342. [\[CrossRef\]](#) [\[PubMed\]](#)
46. Woolcock, A.D.; Keenan, A.; Cheung, C.; Christian, J.A.; Moore, G.E. Thrombocytosis in 715 Dogs (2011–2015). *J. Vet. Intern. Med.* **2017**, *31*, 1691–1699. [\[CrossRef\]](#)
47. Phipps, W.E.; de Laforcade, A.M.; Barton, B.A.; Berg, J. Postoperative thrombocytosis and thromboelastographic evidence of hypercoagulability in dogs undergoing splenectomy for splenic masses. *J. Am. Vet. Med. Assoc.* **2020**, *256*, 85–92. [\[CrossRef\]](#) [\[PubMed\]](#)
48. Toroghi, N.; Abbasian, L.; Nourian, A.; Davoudi-Monfared, E.; Khalili, H.; Hasannezhad, M.; Ghiasvand, F.; Jafari, S.; Emadi-Kouchak, H.; Yekaninejad, M.S. Comparing efficacy and safety of different doses of dexamethasone in the treatment of COVID-19: A three-arm randomized clinical trial. *Pharmacol. Rep.* **2022**, *74*, 229–240. [\[CrossRef\]](#)
49. Shoenfeld, Y.; Gurewich, Y.; Gallant, L.A.; Pinkhas, J. Prednisone-induced leukocytosis. *Am. J. Med.* **1981**, *71*, 773–778. [\[CrossRef\]](#)
50. Schulz, B.S.; Hupfauer, S.; Ammer, H.; Sauter-Louis, C.; Hartmann, K. Suspected side effects of doxycycline use in dogs—A retrospective study of 386 cases. *Vet. Rec.* **2011**, *169*, 229. [\[CrossRef\]](#)
51. van Avondt, K.; Nur, E.; Zeerleder, S. Mechanisms of haemolysis-induced kidney injury. *Nat. Rev. Nephrol.* **2019**, *15*, 671–692. [\[CrossRef\]](#) [\[PubMed\]](#)
52. Pantchev, N.; Schnyder, M.; Vrhovec, M.G.; Schaper, R.; Tsachev, I. Current Surveys of the Seroprevalence of *Borrelia burgdorferi*, *Ehrlichia canis*, *Anaplasma phagocytophilum*, *Leishmania infantum*, *Babesia canis*, *Angiostrongylus vasorum* and *Dirofilaria immitis* in Dogs in Bulgaria. *Parasitol. Res.* **2015**, *114*, 117–130. [\[CrossRef\]](#) [\[PubMed\]](#)

53. Strobl, A.; Pantchev, N.; Martin, L.; Guija-De-Arespacochaga, A.; Hinney, B.; Fuehrer, H.-P.; Leschnik, M. Co-infection with *Babesia canis* and *Babesia gibsoni* in a dog. *Acta Vet. Hung.* **2021**, *69*, 347–353. [[CrossRef](#)]
54. René-Martellet, M.; Moro, C.V.; Chêne, J.; Bourdoiseau, G.; Chabanne, L.; Mavingui, P. Update on epidemiology of canine babesiosis in Southern France. *BMC Vet. Res.* **2015**, *11*, 223. [[CrossRef](#)]
55. Jefferies, R.; Ryan, U.M.; Irwin, P.J. PCR-RFLP for the detection and differentiation of the canine piroplasm species and its use with filter paper-based technologies. *Vet. Parasitol.* **2007**, *144*, 20–27. [[CrossRef](#)]

Disclaimer/Publisher’s Note: The statements, opinions and data contained in all publications are solely those of the individual author(s) and contributor(s) and not of MDPI and/or the editor(s). MDPI and/or the editor(s) disclaim responsibility for any injury to people or property resulting from any ideas, methods, instructions or products referred to in the content.