


Use and meaning of the anatomical terms „Plexus choroideus” and „Tela choroidea” in veterinary and human medicine

Maximilian Koellmberger, Kirsti Witter 

Department of Biological Sciences and Pathobiology, University of Veterinary Medicine, Vienna, Austria

[Received: 5 January 2024; Accepted: 3 March 2024; Early publication date: 25 March 2024]

The anatomical terms Plexus chor(i)oideus (CP) and Tela chor(i)oidea (TC) are listed without explanations in the official nomenclature handbooks Terminologia Neuroanatomica and Nomina Anatomica Veterinaria. Definitions of CP and TC exhibit discrepancies in medical dictionaries and anatomy handbooks. The aim of our study was to analyse this problem in detail and to discuss a possible unified use of the terms in science and teaching.

The authors conducted a systematic literature review based on the Preferred Reporting Items for Systematic Reviews and Meta-Analyses, identifying and analysing relevant scholarly articles. Additionally, comprehensive original handbooks on human and veterinary anatomy in English and other European languages were examined. The definitions of the terms CP and TC differed considerably between articles and did not match the most frequently given explanations in handbooks. In general use, it seems to have become accepted that TC represents the smooth, thin part of the roof of the third and fourth ventricles, and CP the frond- or fringe-like vascularised structures invaginated into the lateral, third and fourth ventricles. However, it is controversial which tissue layers should be included in their description. Etymologically, only the vascular network should be termed (choroid) plexus, but embryologically and functionally, epithelium, pial connective tissue, and vascular network form an inseparable entity. Similarly, the smooth part of the ventricle roof consists of a (less) vascularised pia-derived stroma and lining epithelium. Including all these layers in the definition of CP as well as TC might be advisable and also corresponds to the use of the terms in clinical context. (Folia Morphol 2024; 83, 4: 757–770)

Keywords: plexus choroideus, tela choroidea, terminology, nomenclature, choroid plexus, choroid membrane, systematic literature review, mammals

INTRODUCTION

The anatomical terms Plexus chor(i)oideus (choroid plexus, CP) and Tela chor(i)oidea (TC) are both listed without further explanations or definitions in the official handbooks on human and veterinary (neu-

ro)anatomical nomenclature Terminologia Neuroanatomica [34] and Nomina Anatomica Veterinaria [111].

The recently updated Terminologia Neuroanatomica (integrating the chapter on nervous tissue of the formerly separate human histological nomenclature)

Address for correspondence: Kirsti Witter, Anatomy, Department of Biological Sciences and Pathobiology, University of Veterinary Medicine, Veterinärplatz 1, 1210 Vienna, Austria; e-mail: kirsti.witter@vetmeduni.ac.at

This article is available in open access under Creative Common Attribution-Non-Commercial-No Derivatives 4.0 International (CC BY-NC-ND 4.0) license, allowing to download articles and share them with others as long as they credit the authors and the publisher, but without permission to change them in any way or use them commercially.

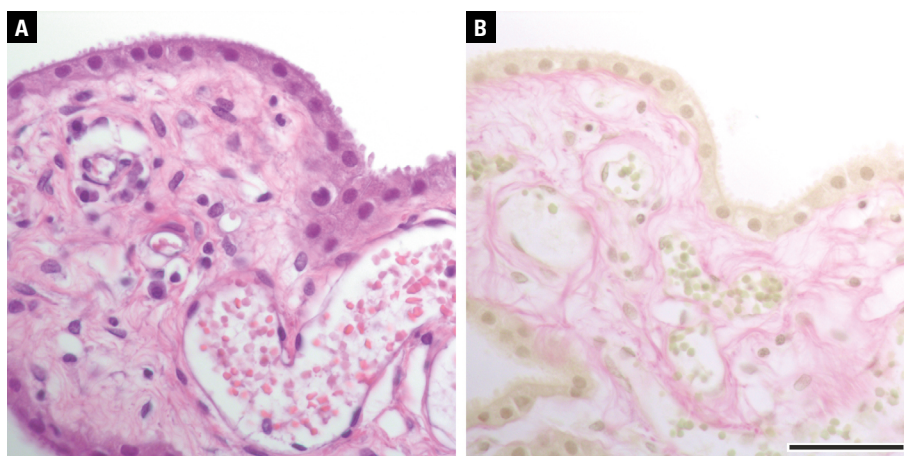


Figure 1. Plexus choroideus ventriculi quarti of an adult dog — detail of one villus. Histological section, (A) haematoxylin-eosin, (B) van Gieson staining. Note the considerable amount of connective tissue (shown in pink in B) surrounding the vascular network, and the cuboidal epithelium covering the villus. Scale bar: 50 μ m.

assigns TC and CP to the same level of hierarchy, both subordinate to the term *Pia mater cranialis*. Terminologia Neuroanatomica specifies *Plexus choroideus ventriculi quarti, tertii, and lateralis*, but only *Tela choroidea ventriculi quarti and tertii*.

Similarly, *Nomina Anatomica Veterinaria* lists *Tela choroidea ventriculi quarti, Tela choroidea ventriculi tertii, and Plexus choroideus ventriculi quarti, tertii, and lateralis* at the same hierarchical level immediately subordinate to *Pia mater encephali*. Additionally, *Tela choroidea ventriculi quarti* is immediately subordinate to the entry *Ventriculus quartus* and *Tela choroidea ventriculi tertii* to the entry *Diencephalon*. The *Nomina Anatomica Veterinaria* do not list CP under the entries for the single ventricles or brain parts.

Nomina Histologica Veterinaria [51] assigns the term *Plexus choroideus* to the same level of hierarchy as *Pia mater*, but TC as subordinate to CP.

From an etymological point of view, “plexus” means braid or plexus, in anatomy an interlacing of nerves, vessels, or fibres [102]. Thus, in case of the CP it should designate the capillary net of the cauliflower-like structures in the fourth, third, and lateral ventricles. However, usually it seems to be used for the complete cauliflower-like structure or at least for more than one of its layers (Fig. 1) [e.g. 43, 50, 52, 95, 107]. The Latin word “tela” (web, loom) designates “tissue layer”, not providing any linguistic clue for the actual structure. As an English equivalent, choroid membrane is suggested [34].

Neither Terminologia Neuroanatomica nor *Nomina Histologica Veterinaria* provide any information on layers or tissues forming TC or CP, except listing the

existence of a choroid epithelium (*Epithelium plexus choroidei* [51] or *Epithelium choroideum* [34]) with choroid epithelial cells (*Ependymocytus choroideus* [34, 51] or *Epitheliocytus choroideus* [34]) for the CP, but not the TC.

Even in medical dictionaries, definitions of TC and CP differ slightly or are incomplete. The Webster-Merriam Medical dictionary [76, 77] defines TC as a fold of *Pia mater* roofing a ventricle of the brain, and the CP as a highly vascular portion of the *Pia mater* that projects into the ventricles and secretes cerebrospinal fluid. The French *Vocabulaire Médical* [28] does not provide any definition of CP, but lists TC (*toile choroïdienne*) of the fourth and third ventricle as large folds of the *Pia mater* that invaginate into the crevice between the lower surface of the cerebellum and the roof of the fourth ventricle or into the *Fissura transversa* of the brain, respectively. The English as well as the French medical dictionary disregard the choroid epithelium. According to the German *Pschyrembel* [89], TC is a structure consisting of the roof of the third and fourth ventricle together with the *Pia mater*, forming the basis for the CP. CPs are defined as “vascular networks; structures rich in vessels and nerves derived from the *pia mater* and invaginated into the ventricles, their villous surface being covered with *ependyma*”.

Similar discrepancies could be found when performing a cursory search in handbooks on human and veterinary anatomy.

There are few analyses of the terminology of CP [29 and selected references therein], but to our knowledge, there has been no overview defining

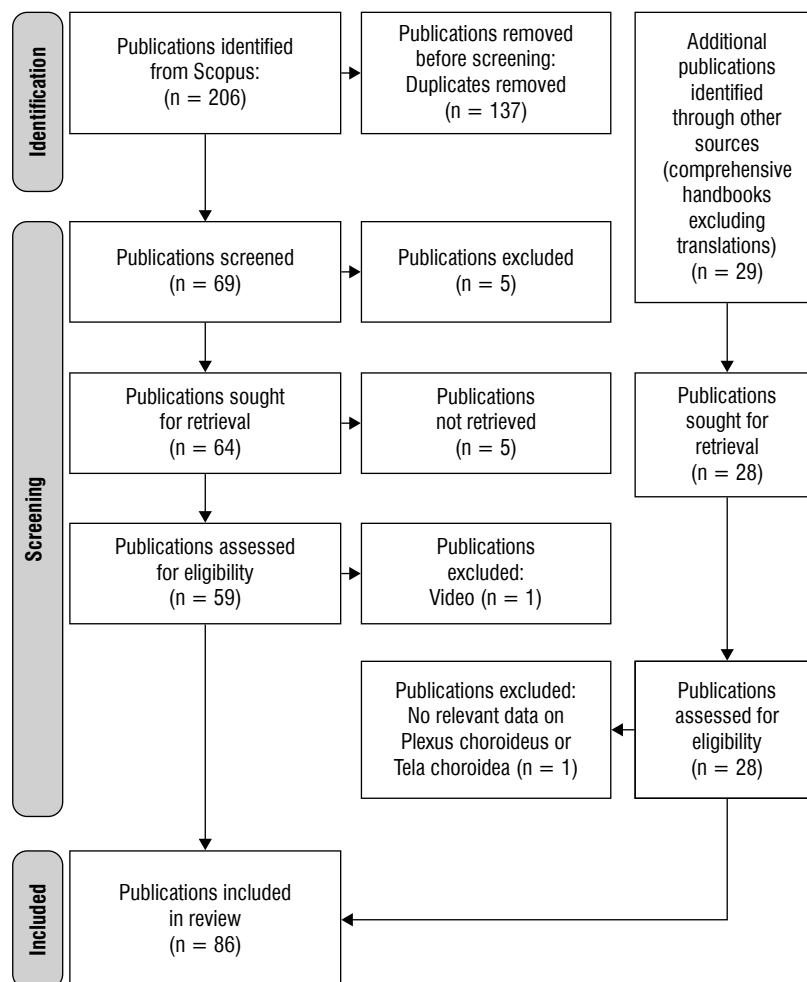


Figure 2. Flow chart illustrating the exclusion process for publications (adapted from PRISMA guidelines [79]).

both CP and TC and explaining their relationship. The inconsistencies in CP and TC nomenclature have been pointed out before [102]. To research this issue, we conducted a systematic literature review to find publications using both terms and analysed how they are characterised and differentiated. Comprehensive original handbooks on human and veterinary anatomy in English and other European languages were included in the search. The aim of our study was to provide a suggestion on how to unify the use of the respective terms CP and TC in science and teaching.

MATERIALS AND METHODS

As suggested for evidence-based anatomy studies [45], the material was identified and analysed based on the Preferred Reporting Items for Systematic Reviews and Meta-Analyses (PRISMA) guidelines [79].

The database Scopus® was searched using the following search strings:

TITLE-ABS-KEY (plexus W/5 chorioid*) AND TITLE-ABS-KEY (tela W/5 chorioid*), TITLE-ABS-KEY (plexus W/5 chorioid*) AND TITLE-ABS-KEY (tela W/5 choroid*), TITLE-ABS-KEY (plexus W/5 chorioid*) AND TITLE-ABS-KEY (tela W/5 chorioid*), TITLE-ABS-KEY (plexus W/5 choroid*) AND TITLE-ABS-KEY (tela W/5 choroid*). The phrasing ensured that both CP and TC were featured in a prominent position, i.e. in either title, abstract, or keywords, regardless of the spelling (choroid-/chorioid-), in English as well as in Latin (Plexus choroideus/choroid plexus). A preliminary search using equivalent search strings in Pubmed® yielded fewer results without differences to the Scopus search. Therefore, only Scopus results (“articles”) were subjected to further analysis. No time limit was set for the search, which was carried out on 23/08/2022. Additionally, comprehensive original handbooks (“handbooks”) on human and veterinary anatomy in English and other European languages were identified, excluding translations (Fig. 2).

All publications were screened as shown in Figure 2. Duplicates that had to be excluded arose from the use of only slightly differing search strings. Other formal reasons for the exclusion of publications from further analysis were the language (Japanese), ineligible format (video), and unavailability of full text.

A total of 86 publications were analysed in detail. The publications were classified according to their type and their main scientific field, separately for human and veterinary medicine. They were searched for the terms CP and TC and directly written or indirectly implied definitions for both terms, including their possible synonymous use. The results of this analysis were recorded.

Translation of relevant paragraphs was necessary for all languages except English and German. Sources in Slavic languages were translated by KW, all other sources by MK.

Statistics

The use of the terms CP and TC and, if given, their definitions were summarised and sorted into categories based on similarities of the record entries. The acquired data were analysed using descriptive statistics. The frequency of use of each definition and of the combination of CP and TC definitions was determined in relation to the total number of publications. The resulting percentages were represented using diagrams. Handbooks and articles were analysed separately as well as combined. Additionally, the publications were divided into groups by their scientific disciplines, countries of origin, and decades of publication and evaluated as described above.

RESULTS

In total, 86 publications were analysed, including 28 handbooks [3, 4, 8, 10, 14–16, 20, 25, 30, 32, 33, 38, 42, 55–57, 63, 82, 84, 86–88, 96, 97, 101, 104, 106] and 58 articles (48 original articles [1, 2, 5–7, 18, 19, 21–24, 26, 27, 31, 37, 39, 40, 43, 44, 46, 47, 49, 50, 52–54, 59, 62, 64, 66–75, 78, 79, 81, 95, 99, 102, 105, 107–110], 9 case reports [9, 11, 13, 17, 36, 48, 60, 90, 94] and one book chapter [6]). Publication dates of articles ranged from June 1927 [44] to December 2021 [95, 108]. The oldest included handbook was published in 1897 [16]. Languages of handbooks included German [4, 10, 32, 56, 63, 86, 88, 101, 106], English [16, 30, 42, 84, 97], Czech [20, 57, 82], Serbo-Croatian [96], Romanian [38], French [8, 15, 25, 104], Polish [14, 55], and Italian [3, 33].

Articles included 28 authored by scientists from institutions in an English-speaking country [1, 2, 6, 9, 11, 17, 18, 24, 36, 39, 40, 44, 46, 47, 52–54, 59, 70, 72–75, 78, 94, 102, 105, 108], 12 in countries of the Romance language family [5, 19, 22, 23, 49, 50, 66–69, 109, 110], 6 in Asia [37, 48, 64, 71, 81, 90, 95], 3 in a German-speaking country [26, 62, 99], 2 in Africa [7, 31], 2 in Eastern Europe [21, 60], 2 in South America [13, 107], and one in Scandinavia [43]. No correlation was found between the country of origin of the respective publication and use of definitions for CP and TC.

While handbooks covered exclusively the nervous system of humans and domestic mammals, articles dealt with humans and different mammals, except for 2 articles on frogs [53, 78] and 2 on zebrafish [27, 37]. Articles on the fish brain [27, 37] had to be excluded from further analysis because the anatomy and development of the fish brain deviates significantly from that of other vertebrates [35].

All handbooks mentioned the CP, but in 2 of them, the term TC was not included [16, 30]. Similarly, all articles mentioned the CP, but the term TC was found in the text body of only 57 articles, the remaining one listing the TC exclusively in the keywords [44]. In none of the 86 publications were both terms used synonymously.

Based on the interpretation of the terms CP and TC, the publications were classified into 11 categories separately for each structure. The categories included: "no definition", "only epithelium", "epithelium and blood vessels", "epithelium, blood vessels and pia mater", "only blood vessels", "only pia mater", "surgical wording", "incomplete, but epithelium is mentioned as a part", "incomplete, but pia mater is mentioned as a part", "incomplete, but epithelium and blood vessels are mentioned as parts", and "non-pial-connective-tissue". For graphical presentation the 3 categories containing incomplete definitions were merged into one. If not explicitly specified otherwise, the phrasing "covered by epithelium" was understood as including the epithelium. Two publications [30, 98] were put into 2 CP defining categories due to different possible interpretations of the describing phrases. Examples of the wording used to define CP and TC for each category (excluding "no definition") are given in Table 1. A complete list can be found in Supplement 1.

The number of occurrences of each definition is shown in Figure 3. The most frequently used definition

Table 1. Example phrases defining the terms *Tela choroidea* (TC) and choroid plexus (CP) for the categories the publications were classified into.

Category	Wording example
CP, only epithelium [2, 36, 53, 54, 59, 70, 78]	"These ependymal cells eventually differentiate into the choroid plexus of the ventricular system" [36]
TC, only epithelium [2, 4, 7, 9, 30, 53, 54, 59, 64, 70]	"The thin epithelial roof, the <i>Tela choroidea ventriculi tertii</i> , spans between the striae medullares of both thalami" [4]
CP, epithelium and blood vessels [4, 7, 46, 64, 66, 109, 110]	"Effectively, the choroid plexuses are formed by proliferation of the pial vessels accompanied, towards the ventricle, by the ependymal membrane which covers them in their totality" [109]
CP, pia mater, epithelium and blood vessels [1, 3, 5, 8, 10, 11, 14, 15, 17, 26, 30, 32, 33, 41, 43, 48, 52, 56, 82, 86, 95, 101, 106, 107]	"From the vascular layer of the leptomeninges, the pia mater, blood capillaries lower themselves villous and knot-like into the thin walls and protrude into the ventricle. The capillary loops are covered by single-layered ependyma and are called <i>Plexus choroideus</i> . The choroid plexus therefore consist of a lamina choroidea epithelialis and lamina choroidea propria" [86]
TC, pia mater, epithelium and blood vessels [8, 10, 14, 21, 33, 43, 72, 78, 82, 102]	"The wall of the brain ventricles consists only of a thin epithelial layer in these places — the lamina epithelialis, which consists of adapted ependyma. The lamina epithelialis is covered on the outside by pia mater, which is richly spanned by vascular networks; together lamina epithelialis and pia mater form the vascular veil — the lamina choroidea [<i>Tela choroidea</i>]" [82]
CP, only blood vessels [20, 25, 38, 55, 68, 96, 97, 104]	"Considering a structural point of view, the choroid plexuses essentially are constituted of arterioles, venules and webs of capillaries of different calibres, irregularly curled up in themselves" [104]
CP, only pia mater [16, 57, 97, 102, 105]	"Two thickened portions of pia mater" [16]
TC, only pia mater [3, 14, 15, 24–26, 30, 32, 38, 41, 48, 50, 55–57, 60, 63, 75, 86, 90, 96, 97, 101, 104–107]	"The <i>Tela choroidea ventriculi quarti</i> consists of two-layered pia mater, which inserts between the bottom surface of the cerebellum and the roof part of the fourth ventricle" [63]
TC, non-pial-connective tissue [20, 36]	"The <i>Tela choroidea</i> is a plate of connective tissue covered from the ventricle side by ependyma and on its surface by pia mater" [20]
CP and TC, surgical wording [22, 23, 39, 50]	After the choroid plexus was partially removed and the <i>Tela choroidea</i> divided and deflected, the floor of the lateral recess of the fourth ventricle and the convolution of the dorsal cochlear nucleus became visible [23]
CP, Incomplete definition [9, 24, 40, 44, 47, 62, 72, 75, 81, 90]	Anatomical studies employing light microscopy, transmission electron microscopy and scanning electron microscopy have been performed upon the choroidal epithelium. In addition, light and transmission electron microscopic and freeze fracture studies have been executed on the choroidal plexus capillaries" [62]

for the CP (24×) was "epithelium, blood vessels and pia mater" [1, 3, 5, 8, 10, 11, 14, 15, 17, 26, 30, 32, 33, 42, 43, 48, 52, 56, 82, 86, 95, 101, 106, 107] while the TC was most frequently (26×) defined as "only pia mater" [3, 14, 15, 24–26, 32, 38, 42, 48, 50, 55–57, 60, 63, 75, 86, 90, 96, 97, 101, 104–107]. Four definitions were only used for the CP [4, 7, 20, 24, 25, 30, 38, 40, 46, 55, 62, 64, 66, 68, 72, 75, 90, 96, 97, 104, 109, 110] while "non-pial-connective tissue" was only used for the TC [20, 36]. It is noticeable that 32 [1, 5, 6, 11, 13, 17–19, 31, 39, 44, 46, 49, 52, 62, 66–69, 71, 73, 74, 81, 84, 87, 88, 94, 95, 99, 108–110] and 20 publications [6, 13, 18, 19, 21, 31, 49, 60, 63, 67, 69, 71, 73, 74, 84, 87, 88, 94, 99, 108] did not define the CP and TC, respectively.

The various combinations of definitions for CP and TC were also analysed. The most frequently occurring combination, found in 9 handbooks [3, 14, 15, 32, 42, 56, 86, 101, 106] and in 12 publications in total [3, 14, 15, 26, 32, 42, 48, 56, 86, 101, 106, 107], defined CP as consisting of epithelium, pia mater, and blood vessels, while TC was defined as only pia mater.

Six handbooks defined CP as solely blood vessels and TC as only pia mater [25, 38, 55, 96, 97, 104], while another 5 described both CP and TC as epithelium, pia mater, and blood vessels [8, 10, 14, 33, 82]. The most common combination in the articles was no definition of both terms (14 publications) [6, 13, 18, 19, 31, 49, 67, 69, 71, 73, 74, 94, 99, 108], followed by 6 articles in which CP was defined as pia mater and TC was left undefined [1, 5, 11, 17, 52, 95]. Five articles defined both terms as epithelium [2, 53, 54, 59, 70], a combination that was not used in any handbook.

There was an apparent difference regarding the use of definitions for CP and TC when comparing the handbooks and articles (Fig. 4). In the case of the CP definition, "epithelium, blood vessels and pia mater" was used in 47% of the handbooks [3, 8, 10, 14, 15, 30, 32, 33, 42, 56, 82, 86, 101, 106] but only in 17% of the articles [1, 5, 11, 17, 26, 43, 48, 52, 95, 107]. There was also a noticeable difference in defining the CP as only blood vessels. While rather common in the handbooks (27%) [20, 25, 30, 38, 55, 96, 97, 104], only 2% of the articles [68] defined the CP in this way.

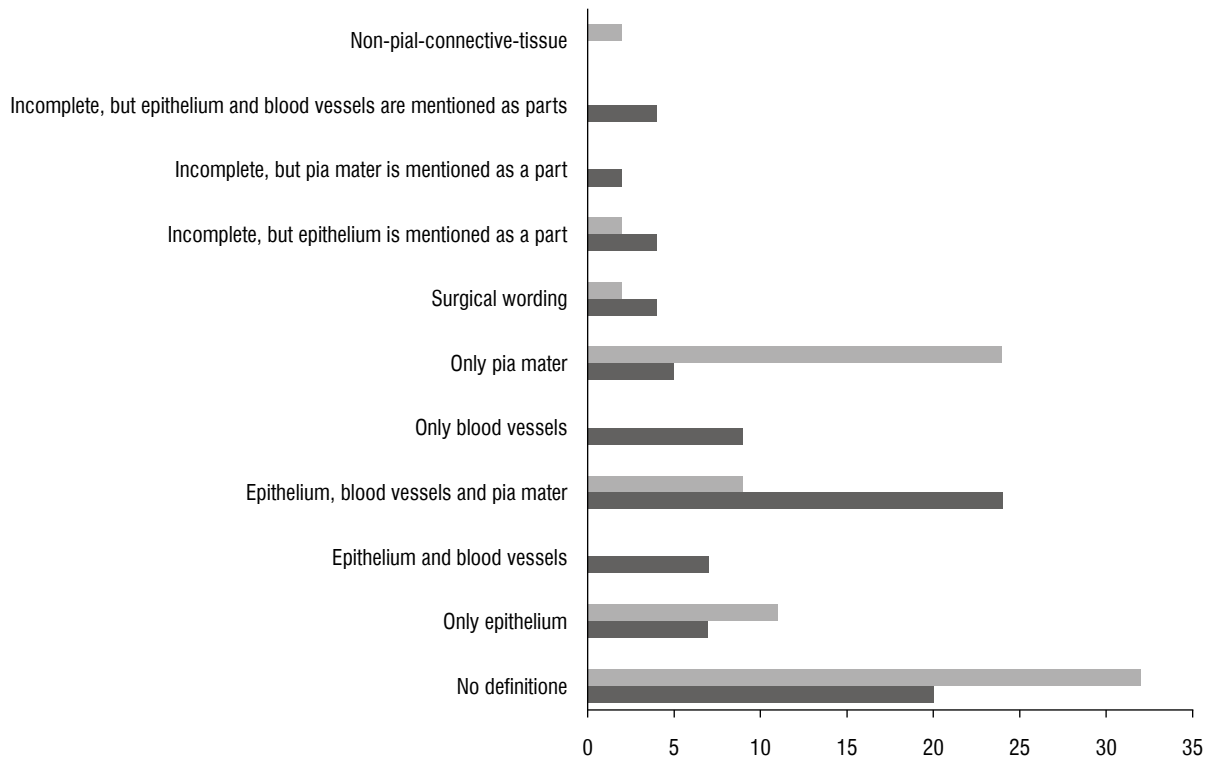


Figure 3. Comparison of choroid plexus (CP; dark grey) and Tela choroidea (TC; light grey) definitions used in scientific publications. Note the high number of publications not defining the terms. If the involved tissue components are specified, CP is most frequently described to include the ependymal epithelium, whereas the TC does not.

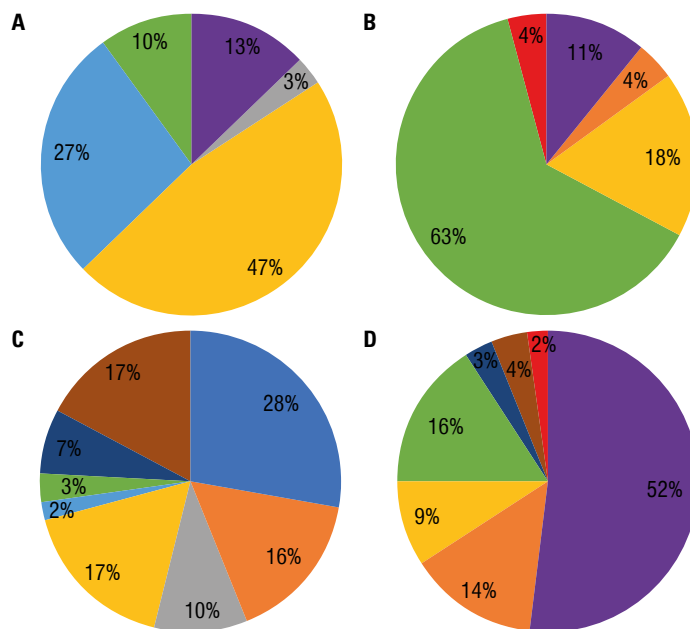


Figure 4. Percentage of use for each definition of the terms choroid plexus (A, C) and Tela choroidea (B, D) differed among the individual source types. A, B. Handbooks; C, D. Articles. Purple: no definition; orange: only epithelium; grey: epithelium and blood vessels; yellow: pia mater, epithelium and blood vessels; light blue: only blood vessels; green: only pia mater; red: non-pial connective tissue; dark blue: surgical wording; brown: incomplete definitions.

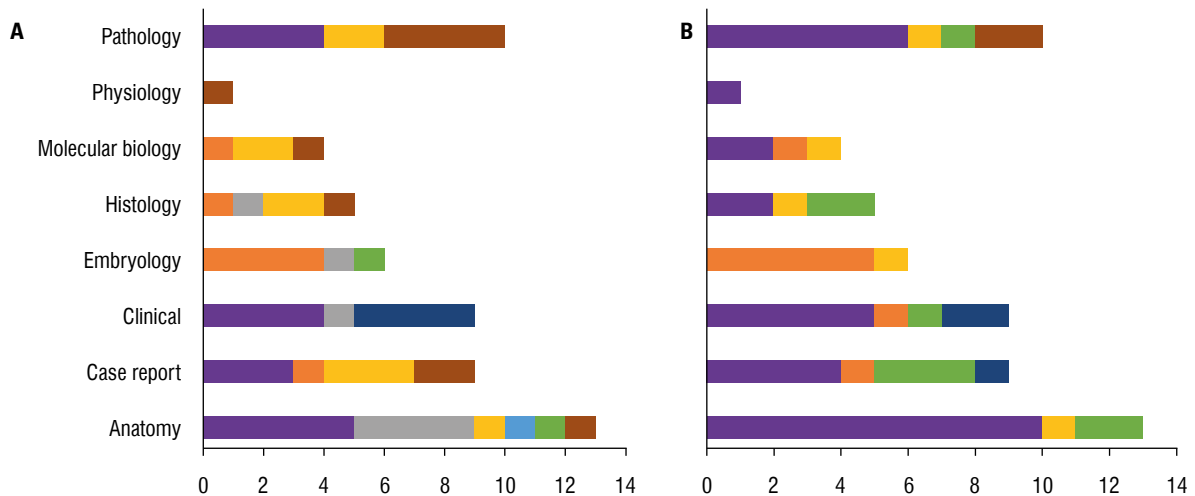


Figure 5. Choroid plexus definitions (A) and Tela choroidea definitions (B) sorted by scientific discipline of the articles. Purple: no definition; orange: only epithelium; grey: epithelium and blood vessels; yellow: pia mater, epithelium and blood vessels; light blue: only blood vessels; green: only pia mater; dark blue: surgical wording; brown: incomplete definitions.

In the case of the TC definition, the most prominent difference occurred for “only pia mater”, which was the most common one in the handbooks (63%) [3, 14, 15, 25, 32, 38, 42, 55–57, 63, 86, 96, 97, 101, 104, 106] while it only featured in 16% of the articles [24, 26, 47, 50, 60, 75, 90, 105, 107]. The percentage of publications without a definition for the terms of interest was noticeably higher for articles (28% and 52% for CP [6, 13, 18, 19, 21, 31, 49, 60, 67, 69, 71, 73, 74, 94, 99, 108] and TC [1, 5, 6, 11, 13, 17–19, 31, 39, 44, 46, 49, 52, 62, 66–69, 71, 73, 74, 81, 94, 95, 99, 108–110], respectively) compared to the handbooks (13% and 11% for CP [63, 84, 87, 88] and TC [84, 87, 88], respectively). For both terms the definitions used in articles were more diverse than in the handbooks. None of the handbooks contained incomplete definitions, while 17% (CP) [9, 24, 40, 44, 47, 62, 72, 75, 81, 90] and 4% (TC) [40, 47] of articles did.

Of the 56 analysed articles, 13 (23%) could be categorised as anatomical [21, 46, 49, 62, 66–69, 71, 105, 107, 109], 9 (16%) as case reports [9, 11, 13, 17, 36, 48, 60, 90, 94], 9 (16%) as clinical [7, 18, 19, 22, 23, 31, 39, 50, 108], 6 (11%) as embryological [2, 53, 54, 64, 70, 102], 5 (9%) as histological [1, 24, 26, 46, 78], 4 (7%) as molecular biological [43, 52, 59, 81], one (2%) as physiological [44], and 10 (18%) as pathological [5, 6, 40, 47, 72–75, 95, 99]. One publication was classified into 2 fields of knowledge: anatomy and histology [46]. Figure 5 demonstrates the usage of the individual definitions for CP and TC across the scientific disciplines. It can be noted that

the “surgical wording” was used exclusively in clinical publications [22, 23, 39, 50]. The definition “epithelium only” predominated in embryological articles for both CP and TC [2, 53, 54, 64, 70]. Otherwise, there appeared to be no correlation between the usage of the definitions and the scientific disciplines.

The change of use of the CP and TC definitions over time is shown in Figure 6. A specific trend could not be identified. However, the definitions used in articles were generally more diverse than in the handbooks, especially noticeable from the 1980s [2, 17, 40, 44, 49, 53, 54, 59, 60, 69, 70, 72, 78, 81, 109, 110]. Interestingly, before the 1980s the TC was generally defined as pia mater in handbooks [16, 32, 38, 57, 97, 104, 106] but not in journal articles.

DISCUSSION

Our systematic review of the literature revealed that the terms CP and TC are indeed used differently in the scientific community, especially regarding the inclusion or exclusion of the ependymal cover and connective tissue of the pia mater.

The text corpus collected for this review is fraught by a number of limitations that should be considered during analysis. While the analysed articles contained both keywords CP and TC, none of them specifically addressed the difference between these structures or the use of the terms. We are aware that several relevant publications might have been overlooked if the CP and TC did not occur in the title, keywords, or abstract [e.g. 12, 80]. The search was limited as described to compare the respective authors’ notion

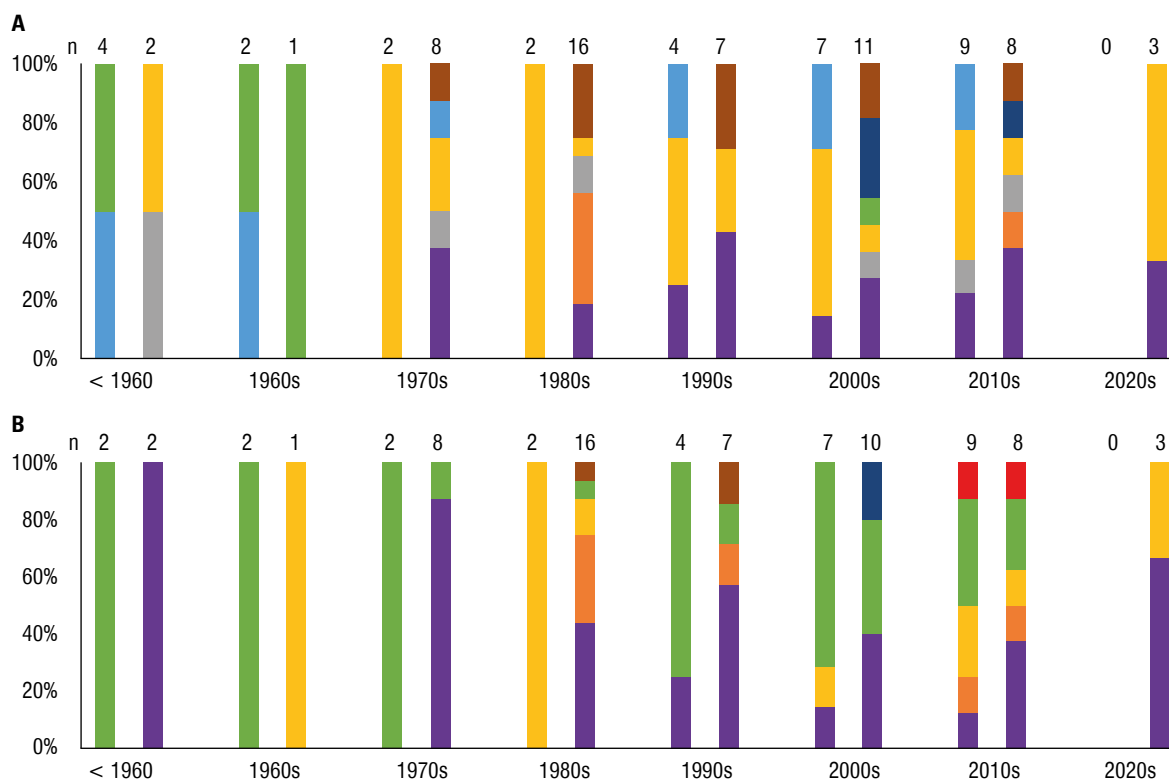


Figure 6. Changed use of choroid plexus (A) and Tela choroidea (B) definitions over time; left column: handbooks; right column: articles; n: number of publications from the indicated decade. Purple: no definition; orange: only epithelium; grey: epithelium and blood vessels; yellow: pia mater, epithelium and blood vessels; light blue: only blood vessels; green: only pia mater; red: non-pial connective tissue; dark blue: surgical wording; brown: incomplete definitions.

of both terms, even if no actual definitions were given. Furthermore, searching for single term definitions would have yielded too many results for the intended in-depth analysis over the complete period. A few publications found by single term search discuss the terminology of CP in detail [29 and references therein, 102], but to our knowledge, there is no equivalent work on TC nomenclature.

The collection of handbooks proved quite difficult. Some relevant handbooks might have escaped our attention. It was neither possible nor practical to collect the first or the most recent editions of the respective books. The oldest tomes were mostly not available for lending and were usually corrected and extended for later editions. The recent editions were often shortened to meet the requirements of a streamlined education in human and veterinary medicine. We analysed therefore the newest but still comprehensive handbook editions, or in the case of rarer material, those that could be sourced. The development of use of the terms CP and TC in books over time (Fig. 6) has therefore only low informative value. A cursory comparison of representative older

and newer editions of one traditional handbook on human [41, 42] and one on veterinary anatomy [85, 86] did not reveal any substantial differences. The explanations of the terms CP and TC were extended in [85, 86] but did not change in their meaning. In [41, 42] the hitherto missing TC definition was added. However, an in-depth historical analysis similar to a recent discussion on the neuroanatomy of the fourth ventricle would be desirable [98].

The interpretation of the wording used to define CP and TC was often challenging. Sentence constructions such as “the plexus is covered by a single layer of epithelial cells” were generally understood to include the epithelium in the forementioned structure [e.g. 46]. In the case of incomplete [9, 24, 40, 44, 47, 62, 72, 75, 81, 90] or missing definitions (most surgical publications), the actual meaning of the terms CP and TC was deduced by implication as best as possible. For the “incomplete” example given in Table 1 [62], it seems that the authors include at least epithelium and capillaries in CP, whereas no information on connective tissue is given. Inconsistencies within the same source were only a problem of the handbooks [14, 30, 97].

In these cases, the various definitions within one source were counted separately for numerical analysis; for example, [97] was included in the categories “only blood vessels” as well as “only pia mater” for CP.

The main difference between explanations of CP and TC in the analysed publications was the inclusion or exclusion of layers or structures. The definitions “vessels only” or “epithelium and vessels” were used exclusively for CP, whereas both TC and CP have been described to consist either only of pia mater, only of epithelium or of epithelium, vessels, and connective tissue (Fig. 3). While there was a preference of definitions in handbooks (CP = “epithelium, blood vessels and pia mater”, TC = “only pia mater”), the meaning of the terms in articles was far more widespread (Fig. 4). Moreover, there was no clear historical trend (Fig. 6). It is therefore not possible to give a clear recommendation for the definition of CP and TC based on the frequency of use or historical development.

None of the analysed publications enlarged directly on the difference between CP and TC. In some cases, the CP was thought to develop from the TC [54, 57], as a vascular plexus inside the invaginating TC [42], or the TC was described as being involved in CP formation [2, 7, 8, 10, 25, 26, 30, 32, 36, 38, 42, 43, 48, 55, 56, 64, 70, 81, 84, 86, 88, 101, 102, 106–108]. The preferred use of the terms by pathologists and surgeons (e.g. “the choroid plexus was then partially removed and the Tela choroidea divided and bent back” [23]) implied a macroscopic distinction rather than one based on the microstructure. A flat, thin dorsal ventricle roof without nervous tissue would be termed TC, whereas the complete cauliflower- or frond-like structures invaginated into the ventricles CP (see, e.g., [112] for illustrative mesoscopic photographs).

The question remains which of the tissue layers shall be regarded as a part of CP and TC.

From an etymological point of view and following the conventions of anatomical nomenclature (cf. *Plexus vasculosus*, *Plexus venosus*; but also *Plexus vertebralis externus/internus*, *Plexus pampiniformis* and the nerve plexus), only the capillary network of the cauliflower-like structures (and possibly the stromal tissue surrounding them) should be termed CP [101]. However, this is only observed by a few publications [20, 25, 38, 55, 68, 96, 97, 104] and does not meet the customs, especially in surgical literature.

From an embryological point of view, publications discussing CP and TC ontogenesis in mammals [2, 42, 53, 54, 64, 70, 102, 103] agree on the general developmental principles: The dorsal roof plate of the cranial neural tube thins in certain regions, forming a single layer of cells. The pia mater anlage with its blood vessels adheres to them. Afterwards, the resulting membrane invaginates into the fourth, third, and lateral ventricles, forming cauliflower-like stromal protrusions containing a prolific vascular net and covered with specialised epithelial cells that are continuous with the ependymal lining of the ventricles. From this point of view, CP as well as TC should both either be defined as including vascularised connective tissue and neuroectodermal epithelium (for CP, see [61, 92]), or both as connective tissue structures excluding the epithelium.

From a functional point of view, there is very little helpful information to distinguish the tissue components of CP and TC. The CP has manifold functions, primarily cerebrospinal fluid production [for review, see 58, 65, 83, 91]. Both CP epithelium and vascularised stroma play a central role in this process. The latter provides the liquid component itself via its fenestrated capillaries, while CP epithelial cells form the blood-cerebrospinal fluid barrier, preventing paracellular transport of substances with their intercellular junctional complexes and creating a unidirectional flow of sodium, bicarbonate, and chloride via special transporter molecules, which powers the transcellular transport of water [65, 83, 91, 93]. Although the CP epithelium is inseparable from the underlying stroma from a morphological (Fig. 1) as well as from a functional point of view, the stroma is sometimes disregarded in CP definition [2, 54, 70].

In contrast to CP, there are virtually no publications on TC function and the involved tissue components. If at all, TC is simply regarded as a part of the ventricle roof [98] involved in CP formation [2, 7, 8, 10, 25, 26, 30, 32, 36, 38, 42, 43, 48, 55, 56, 64, 70, 81, 84, 86, 88, 98, 101, 102, 106–108]. At least in its roof function, epithelium as well as the pia-derived stroma are involved to form the physical barrier.

The function of CP and TC therefore does not provide any arguments for exclusion of tissue layers in their definition. Both structures need epithelium as well as their more (CP) or less (TC) vascularised stroma to fulfil their role. Interestingly we could not find any studies addressing possible differences between CP

and TC epithelium, even if it is known that CP epithelium differs considerably from “normal” ependyma [see, e.g., 42, 59, 101]. TC epithelial cells seem a bit smaller and denser than the large cuboid CP epithelial cells, and some figures in respective publications seem to show a differing metabolic equipment [100].

It remains to be ascertained if the ependymal cells covering the CP differ in shape, molecular composition, and function from the ependymal cells of the TC, and if the connective tissue stroma of both structures can be differentiated from each other and from the normal pia mater covering nervous tissue.

CONCLUSIONS

The definitions of the terms CP and TC differ in different publications. It seems to have become accepted that TC represents the smooth, thin part of the roof of the third and fourth ventricles, and CP the complete frond- or fringe-like vascularised structures invaginated into the lateral, third, and fourth ventricles, but it is controversial which tissue layers should be included in their description. For CP, only the vascular network should be termed plexus from an etymological point of view, but embryologically and functionally, epithelium, pial connective tissue, and vascular network form an inseparable entity. Similarly, the smooth part of the ventricle roof that can be identified macroscopically consists of a (less) vascularised pia-derived stroma and lining epithelium. Including all these layers in the definition of CP as well as TC also corresponds to the use of the terms in clinical context.

ARTICLE INFORMATION AND DECLARATIONS

Author contributions

M. Koellmberger: adaptation and refinement of the study design; searching relevant publications; sourcing the material; translation from Romance languages; data acquisition, manipulation, analysis and interpretation; drafting and critical revision of the article

K. Witter: primary idea and conception of the work; study design; identification and sourcing of additional publications (handbooks); translation from Slavic languages; consultation and supervision; critical revision of the article

Funding

None.

Acknowledgements

We would like to thank all our colleagues that helped with sourcing and translation of the analysed publications, particularly Aleksandra Rozwadowska (Wrocław, Poland), Zbyněk Tonar (Plzeň, Czech Republic), Claudia Wolschrijn (Utrecht, The Netherlands), Hanna Jackowiak (Poznań, Poland), Malan Štrbenc (Ljubljana, Slovenia), Mahtab Bahramsoltani and Maximiliane Schmedding (Berlin, Germany), Stefano Rapino (Pavia, Italy). For their help with retrieving the handbooks we would also like to thank the staff of the university libraries of the University of Veterinary Medicine (Vienna), the Medical University of Vienna and the medical library of the University of Bologna.

Conflict of interest

None declared.

Supplementary material

Supplementary Material is available on [Journal's website](#). This includes:

Supplement 1. Use and meaning of the anatomical terms Plexus choroideus and Tela choroidea in veterinary and human medicine.

REFERENCES

- Allen DJ. Scanning electron microscopy of epiplexus macrophages (Kolmer cells) in the dog. *J Comp Neurol.* 1975; 161(2): 197–213, doi: [10.1002/cne.901610205](https://doi.org/10.1002/cne.901610205), indexed in Pubmed: [1127144](https://pubmed.ncbi.nlm.nih.gov/1127144/).
- Altman J, Bayer SA. Development of the precerebellar nuclei in the rat: I. The precerebellar neuroepithelium of the rhombencephalon. *J Comp Neurol.* 1987; 257(4): 477–489, doi: [10.1002/cne.902570402](https://doi.org/10.1002/cne.902570402), indexed in Pubmed: [3693594](https://pubmed.ncbi.nlm.nih.gov/3693594/).
- Anastasi G. *Trattato di anatomia umana Volume 3 — Neuroanatomia.* Edi Hermes, Milan 2006.
- Anderhuber F, Pera F, Streicher J, Waldeyer — *Anatomie des Menschen: Lehrbuch und Atlas in einem Band.* Walter De Gruyter, Berlin 2012.
- Argenta G, Merigliano D. Pseudotumor of the brain caused by fibro-adhesive inflammation of the choroid plexus of the tela of the 4th ventricle. *Riv Neurol.* 1958; 28(6): 642–654, indexed in Pubmed: [13646508](https://pubmed.ncbi.nlm.nih.gov/13646508/).
- Avgerooulos NG, Henson JW. Meningeal Sarcomas. In: Raghavan DG, Brecher ML, Johnson DH, Meropol NJ, Moots PL, Rose PG, Mayer IA. ed. *Textbook of Uncommon Cancer*, 3rd ed. John Wiley & Sons, Hoboken 2006: 626–637.
- Azab WA, Shohoud SA, Elmansoury TM, et al. Blake's pouch cyst. *Surg Neurol Int.* 2014; 5: 112, doi: [10.4103/2152-7806.137533](https://doi.org/10.4103/2152-7806.137533), indexed in Pubmed: [25101207](https://pubmed.ncbi.nlm.nih.gov/25101207/).
- Barone R. *Anatomie comparée de mammifères domestiques: 6. Neurologie, 1: Système nerveux central.* Vigot Frères, Paris 2004.

9. Bendon RW, Dungy-Poythress L, Miodovnik M, et al. Perinatal pathology of interhemispheric cyst with thinned posterior corpus callosum: four cases. *Pediatr Pathol Lab Med*. 1996; 16(2): 299–317, indexed in Pubmed: [9025836](#).
10. Benninghoff A. Anatomie: makroskopische und mikroskopische Anatomie des Menschen 3 Nervensystem, Haut und Sinnesorgane. Urban & Schwarzenberg, Munich 1985.
11. Berry K, Rice J. Traumatic tear of tela choroidea resulting in fatal intraventricular hemorrhage. *Am J Forensic Med Pathol*. 1994; 15(2): 132–137, doi: [10.1097/00000433-199406000-00008](#), indexed in Pubmed: [8074104](#).
12. Bill BR, Korzh V. Choroid plexus in developmental and evolutionary perspective. *Front Neurosci*. 2014; 8: 363, doi: [10.3389/fnins.2014.00363](#), indexed in Pubmed: [25452709](#).
13. Bittencourt AL, De Qu. Pigmented nevus in the central nervous system associated to hydrocephalus and giant pigmented nevus of the skin. *Patologia*. 1976; 14(3): 207–213.
14. Bochenek A, Reicher M. Anatomia człowieka, Tom 4. PZWL Wydawnictwo Lekarskie, Warsaw 2014.
15. Bossy J. Anatomie clinique: Neuro-anatomie. Springer Verlag France, Paris 2005.
16. Bradley OC. Outlines of Veterinary Anatomy Part III. The Head and Neck. Baillière, Tindall & Cox, London 1897.
17. Britt RH, Silverberg GD, Enzmann DR, et al. Third ventricular choroid plexus arteriovenous malformation simulating a colloid cyst. Case report. *J Neurosurg*. 1980; 52(2): 246–250, doi: [10.3171/jns.1980.52.2.0246](#), indexed in Pubmed: [7351565](#).
18. Calabrò F, Arcuri T, Jinkins JR. Blake's pouch cyst: an entity within the Dandy-Walker continuum. *Neuroradiology*. 2000; 42(4): 290–295, doi: [10.1007/s002340050888](#), indexed in Pubmed: [10872175](#).
19. Chibbaro S, Champeaux C, Poczoz P, et al. Anterior trans-frontal endoscopic management of colloid cyst: an effective, safe, and elegant way of treatment. Case series and technical note from a multicenter prospective study. *Neurosurg Rev*. 2014; 37(2): 235–41; discussion 241, doi: [10.1007/s10143-013-0508-4](#), indexed in Pubmed: [24352893](#).
20. Čihák R. Anatomie 3. Grada, Praha 2016.
21. Ciołkowski M, Sharifi M, Tarka S, et al. Median aperture of the fourth ventricle revisited. *Folia Morphol*. 2011; 70(2): 84–90, indexed in Pubmed: [21630228](#).
22. Colletti V, Carner M, Fiorino F, et al. Retrosigmoid approach for auditory brainstem implant. *J Laryngol Otol Suppl*. 2000; 23(27): 37–40, doi: [10.1258/0022215001904707](#), indexed in Pubmed: [11211436](#).
23. Colletti V, Fiorino F, Carner M, et al. Auditory brainstem implantation: the University of Verona experience. *Otolaryngol Head Neck Surg*. 2002; 127(1): 84–96, doi: [10.1067/mhn.2002.126723](#), indexed in Pubmed: [12161736](#).
24. Cummings TJ, Burchette JL, McLendon RE. CD34 and dural fibroblasts: the relationship to solitary fibrous tumor and meningioma. *Acta Neuropathol*. 2001; 102(4): 349–354, doi: [10.1007/s004010100389](#), indexed in Pubmed: [11603810](#).
25. Delmas A, Rouvière H. Anatomie humaine. Descriptive, topographique et fonctionnelle Tome IV, Système nerveux central, voies et centres nerveux. Masson, Luçon 2002.
26. Dermietzel R. Demonstration of complex endothelial and perivascular system of membrane contacts in choroid plexus. *Verh Anat Ges*. 1976(70 Pt 1): 461–469, indexed in Pubmed: [1023599](#).
27. D'Gama PP, Qiu T, Cosacak MI, et al. Diversity and function of motile ciliated cell types within ependymal lineages of the zebrafish brain. *Cell Rep*. 2021; 37(1): 109775, doi: [10.1016/j.celrep.2021.109775](#), indexed in Pubmed: [34610312](#).
28. Dictionnaire de l'Académie Nationale de Médecine. Toile Choroidienne du Quatrième Ventricle. <http://dictionnaire.academie-medicine.fr/search/results?titre=toile%20choro%C3%AFdiene%20du%20quatri%C3%A8me%20ventricule> (24.04.2023).
29. Duque-Parra J, Castillo-Ramírez S, Marín-Arias J. El Plexo Coroideo: Historia, Estructura, Función, Etimología y Propuesta de Cambio Terminológico. *Int J Morphol*. 2020; 38(6): 1577–1579, doi: [10.4067/s0717-95022020000601577](#).
30. Dyce K, Sack W, Wensing CJG. Textbook of Veterinary Anatomy. Elsevier Saunders, St Louis 2010.
31. El-Bahy K. Telovelar approach to the fourth ventricle: operative findings and results in 16 cases. *Acta Neurochir (Wien)*. 2005; 147(2): 137–142; discussion 142, doi: [10.1007/s00701-004-0407-0](#), indexed in Pubmed: [15605202](#).
32. Ellenberger W, Baum H. Handbuch der vergleichenden Anatomie der Haustiere. Springer, Berlin 1977.
33. Esposito V, Papa M, Passiatore C, De Lu, Mezzogiorno A. Anatomia umana: 3, Sistema nervoso, organi di senso. Piccin-Nuova Libreria, Napoli 2010.
34. Federative International Programme for Anatomical Terminology. Terminologia Neuroanatomica 2017.
35. Fogueira M, Bayley P, Navratilova P, et al. Morphogenesis underlying the development of the everted teleost telencephalon. *Neural Dev*. 2012; 7: 32, doi: [10.1186/1749-8104-7-32](#), indexed in Pubmed: [22989074](#).
36. Gabel BC, Levy ML, Crawford JR. Delayed diagnosis of enhancing posterior fossa tumors mimicking the tela choroidea of the fourth ventricle. *World Neurosurg*. 2015; 84(3): 865.e1–865.e5, doi: [10.1016/j.wneu.2015.03.054](#), indexed in Pubmed: [25839397](#).
37. García-Lecea M, Kondrychyn I, Fong SH, et al. In vivo analysis of choroid plexus morphogenesis in zebrafish. *PLoS One*. 2008; 3(9): e3090, doi: [10.1371/journal.pone.0003090](#), indexed in Pubmed: [18769618](#).
38. Ghetie V. Anatomia animalelor domestice. Editura Săditică și Pedagogică, Bucarest 1967.
39. Menovsky T, Vries Jde, Wurzer J, et al. Intraoperative ventricular puncture during supraorbital craniotomy via an eyebrow incision. *J Neurosurg*. 2006; 105(3): 485–486, doi: [10.3171/jns.2006.105.3.485](#).
40. Gotow T, Hashimoto PH. Fine structure of ependymal cysts in and around the area postrema of the rat. *Cell Tissue Res*. 1980; 206(2): 303–318, doi: [10.1007/BF00232774](#), indexed in Pubmed: [7388894](#).
41. Gray H. Anatomy descriptive and surgical. John W. Parker and Son, London 1858.
42. Gray H, Williams PL. Gray's anatomy: the anatomical basis of medicine and surgery. Churchill Livingstone, Edinburgh 1995.

43. Hadzic A, Nguyen TD, Hosoyamada M, et al. The lactate receptor HCA is present in the choroid plexus, the tela choroidea, and the neuroepithelial lining of the dorsal part of the third ventricle. *Int J Mol Sci.* 2020; 21(18), doi: [10.3390/ijms21186457](https://doi.org/10.3390/ijms21186457), indexed in Pubmed: [32899645](https://pubmed.ncbi.nlm.nih.gov/32899645/).
44. Harbut RE, Johanson CE. Third ventricle choroid plexus function and its response to acute perturbations in plasma chemistry. *Brain Res.* 1986; 374(1): 137–146, doi: [10.1016/0006-8993\(86\)90402-6](https://doi.org/10.1016/0006-8993(86)90402-6), indexed in Pubmed: [3719323](https://pubmed.ncbi.nlm.nih.gov/3719323/).
45. Henry BM, Tomaszewski KA, Walocha JA. Methods of Evidence-Based Anatomy: a guide to conducting systematic reviews and meta-analysis of anatomical studies. *Ann Anat.* 2016; 205: 16–21, doi: [10.1016/j.aanat.2015.12.002](https://doi.org/10.1016/j.aanat.2015.12.002), indexed in Pubmed: [26844627](https://pubmed.ncbi.nlm.nih.gov/26844627/).
46. Herring PT. The pineal region of the mammalian brain: its morphology and histology in relation to function. *Q J Exp Physiol.* 1927; 17(1): 125–147, doi: [10.1113/expphysiol.1927.sp000404](https://doi.org/10.1113/expphysiol.1927.sp000404).
47. Ho KL, Garcia JH. Colloid cysts of the third ventricle: ultrastructural features are compatible with endodermal derivation. *Acta Neuropathol.* 1992; 83(6): 605–612, doi: [10.1007/BF00299409](https://doi.org/10.1007/BF00299409), indexed in Pubmed: [1636378](https://pubmed.ncbi.nlm.nih.gov/1636378/).
48. Huh JiS, Hwang YS, Yoon SH, et al. Lateral ventricular diverticulum extending into supracerebellar cistern from unilateral obstruction of the foramen of monro in a neonate. *Pediatr Neurosurg.* 2007; 43(2): 115–120, doi: [10.1159/000098384](https://doi.org/10.1159/000098384), indexed in Pubmed: [17337923](https://pubmed.ncbi.nlm.nih.gov/17337923/).
49. Hunt H. Vascular abnormalities in a domestic cat (*Felis domestica*). *The Anatomical Record.* 2005; 16(2): 87–92, doi: [10.1002/ar.1090160205](https://doi.org/10.1002/ar.1090160205).
50. Iacoangeli M, di Somma LG, Di Rienzo A, et al. Combined endoscopic transforaminal-transchoroidal approach for the treatment of third ventricle colloid cysts. *J Neurosurg.* 2014; 120(6): 1471–1476, doi: [10.3171/2014.1.JNS131102](https://doi.org/10.3171/2014.1.JNS131102), indexed in Pubmed: [24605835](https://pubmed.ncbi.nlm.nih.gov/24605835/).
51. International Committee on Veterinary Histological Nomenclature to the World Association of Veterinary Anatomists: Nomina Histologica Veterinaria. 2017. https://www.wava-amav.org/downloads/NHV_2017.pdf (20.01.2024).
52. Jolly RD, Marshall NR, Perrott MR, et al. Intracisternal enzyme replacement therapy in lysosomal storage diseases: routes of absorption into brain. *Neuropathol Appl Neurobiol.* 2011; 37(4): 414–422, doi: [10.1111/j.1365-2990.2010.01158.x](https://doi.org/10.1111/j.1365-2990.2010.01158.x), indexed in Pubmed: [21175738](https://pubmed.ncbi.nlm.nih.gov/21175738/).
53. Jones HC, Jopling CA. The development of interependymal pores in the rhombencephalic posterior tela in late embryonic, larval and metamorphosing stages of *Rana pipiens*. *Brain Res.* 1983; 283(2-3): 121–130, doi: [10.1016/0165-3806\(83\)90168-2](https://doi.org/10.1016/0165-3806(83)90168-2), indexed in Pubmed: [6601973](https://pubmed.ncbi.nlm.nih.gov/6601973/).
54. Kato M, Soprano DR, Makover A, et al. Localization of immunoreactive transthyretin (prealbumin) and of transthyretin mRNA in fetal and adult rat brain. *Differentiation.* 1986; 31(3): 228–235, doi: [10.1111/j.1432-0436.1986.tb00402.x](https://doi.org/10.1111/j.1432-0436.1986.tb00402.x), indexed in Pubmed: [3533688](https://pubmed.ncbi.nlm.nih.gov/3533688/).
55. Kobryń H, Kobryńczuk F. *Anatomia zwierząt, tom 3. Wydawnictwo Naukowe PWN, Warsaw 2004.*
56. Koch T. *Lehrbuch der Veterinär-Anatomie Band III Die großen Versorgungs- und Steuerungssysteme. Gustav Fischer Verlag, Stuttgart 1993.*
57. Kolda J, Komárek V. *Neurologie. Státní pedagogické, Praha 1962: Praha.*
58. Kompaníková P, Bryja V. Regulation of choroid plexus development and its functions. *Cell Mol Life Sci.* 2022; 79(6): 304, doi: [10.1007/s00018-022-04314-1](https://doi.org/10.1007/s00018-022-04314-1), indexed in Pubmed: [35589983](https://pubmed.ncbi.nlm.nih.gov/35589983/).
59. Kondziolka D, Bilbao JM. An immunohistochemical study of neuroepithelial (colloid) cysts. *J Neurosurg.* 1989; 71(1): 91–97, doi: [10.3171/jns.1989.71.1.0091](https://doi.org/10.3171/jns.1989.71.1.0091), indexed in Pubmed: [2472473](https://pubmed.ncbi.nlm.nih.gov/2472473/).
60. Kotwica Z, Jagodziński Z, Polis L. Meningiomas of the lateral ventricle. *Neurochirurgia (Stuttg).* 1985; 28(5): 199–201, doi: [10.1055/s-2008-1054199](https://doi.org/10.1055/s-2008-1054199), indexed in Pubmed: [4058635](https://pubmed.ncbi.nlm.nih.gov/4058635/).
61. Kressin M, Brehm R, Schnorr B. *Embryologie der Haustiere. Georg Thieme Verlag, Stuttgart 2019.*
62. Lametschwandtner A, Albrecht U, Adam H. The vascularization of the anuran brain: the choroid plexus of the fourth ventricle. *Acta Zoologica.* 2010; 59(3-4): 229–237, doi: [10.1111/j.1463-6395.1978.tb01037.x](https://doi.org/10.1111/j.1463-6395.1978.tb01037.x).
63. Lanz T, Wachsmuth W. *Kopf. In: Lang J. ed. Praktische Anatomie. Springer, Berlin 1979.*
64. Lucy KM, Harshan KR, Chungath JJ, et al. Histogenesis of diencephalon in goat fetuses. *Ind J Ani Res.* 2009; 43(4): 241–245.
65. Lun MP, Monuki ES, Lehtinen MK. Development and functions of the choroid plexus-cerebrospinal fluid system. *Nat Rev Neurosci.* 2015; 16(8): 445–457, doi: [10.1038/nrn3921](https://doi.org/10.1038/nrn3921), indexed in Pubmed: [26174708](https://pubmed.ncbi.nlm.nih.gov/26174708/).
66. Maillot CI, Koritke JG. Capillary network of the rhombencephalic tela choroidea in man. *Arch Anat Histol Embryol.* 1975; 58: 167–176.
67. Maillot C, Koritke JG, Laude M. The vascular patterns in choroid tela of the fourth ventricle in man. *Arch Anat Histol Embryol.* 1976; 59: 33–70, indexed in Pubmed: [801319](https://pubmed.ncbi.nlm.nih.gov/801319/).
68. Maillot C, Koritke JG, Laude M. The vascular patterns in choroid tela of the fourth ventricle in cat (*Felis domestica*). *Arch Anat Histol Embryol.* 1978; 61: 3–42, indexed in Pubmed: [386954](https://pubmed.ncbi.nlm.nih.gov/386954/).
69. Maillot C, Koritke JG, Laude M. The vascular patterns in choroid tela of the fourth ventricle in dog (*Canis familiaris*) (author's transl). *Arch Anat Histol Embryol.* 1980; 63: 143–178, indexed in Pubmed: [7008697](https://pubmed.ncbi.nlm.nih.gov/7008697/).
70. Makover A, Soprano DR, Wyatt ML, et al. An in situ-hybridization study of the localization of retinol-binding protein and transthyretin messenger RNAs during fetal development in the rat. *Differentiation.* 1989; 40(1): 17–25, doi: [10.1111/j.1432-0436.1989.tb00809.x](https://doi.org/10.1111/j.1432-0436.1989.tb00809.x), indexed in Pubmed: [2744271](https://pubmed.ncbi.nlm.nih.gov/2744271/).
71. Matsushima T, Fukui M, Inoue T, et al. Microsurgical and magnetic resonance imaging anatomy of the cerebello-medullary fissure and its application during fourth ventricle surgery. *Neurosurgery.* 1992; 30(3): 325–330, doi: [10.1227/00006123-199203000-00003](https://doi.org/10.1227/00006123-199203000-00003), indexed in Pubmed: [1620293](https://pubmed.ncbi.nlm.nih.gov/1620293/).
72. Maurizi CP. The pathophysiology of enlarged ventricles in normal pressure communicating hydrocephalus and schizophrenia: a possible therapeutic role for melatonin. *Med Hypotheses.* 1987; 23(1): 61–66, doi: [10.1016/0306-9877\(87\)90182-4](https://doi.org/10.1016/0306-9877(87)90182-4), indexed in Pubmed: [3614004](https://pubmed.ncbi.nlm.nih.gov/3614004/).

73. Maurizi CP. Recirculation of cerebrospinal fluid through the tela choroidea is why high levels of melatonin can be found in the lateral ventricles. *Med Hypotheses*. 1991; 35(2): 154–158, doi: [10.1016/0306-9877\(91\)90041-v](https://doi.org/10.1016/0306-9877(91)90041-v), indexed in Pubmed: [1890974](https://pubmed.ncbi.nlm.nih.gov/1890974/).
74. Maurizi CP. Could antioxidant therapy reduce the incidence of deafness following bacterial meningitis? *Med Hypotheses*. 1999; 52(1): 85–87, doi: [10.1054/mehy.1997.0614](https://doi.org/10.1054/mehy.1997.0614), indexed in Pubmed: [10342676](https://pubmed.ncbi.nlm.nih.gov/10342676/).
75. Maurizi CP. A cycle of cerebrospinal fluid: supporting evidence and theoretical considerations. *Med Hypotheses*. 2000; 54(3): 417–422, doi: [10.1054/mehy.1999.0863](https://doi.org/10.1054/mehy.1999.0863), indexed in Pubmed: [10783477](https://pubmed.ncbi.nlm.nih.gov/10783477/).
76. Merriam-Webster. Choroid Plexus. <https://www.merriam-webster.com/medical/choroid%20plexus> (24.04.2023).
77. Merriam-Webster. Tela choroidea. <https://www.merriam-webster.com/medical/tela%20choroidea> (24.04.2023).
78. Michaels JE, Tornheim PA. Fine structure of the lateral areas of the rhombencephalic tela of the bullfrog, *Rana catesbeiana*. *Cell Tissue Res*. 1980; 211(3): 449–463, doi: [10.1007/BF00234399](https://doi.org/10.1007/BF00234399), indexed in Pubmed: [6968244](https://pubmed.ncbi.nlm.nih.gov/6968244/).
79. Moher D, Liberati A, Tetzlaff J, et al. PRISMA Group. Preferred reporting items for systematic reviews and meta-analyses: the PRISMA statement. *PLoS Med*. 2009; 6(7): e1000097, doi: [10.1371/journal.pmed.1000097](https://doi.org/10.1371/journal.pmed.1000097), indexed in Pubmed: [19621072](https://pubmed.ncbi.nlm.nih.gov/19621072/).
80. Mortazavi MM, Griessenauer CJ, Adeeb N, et al. The choroid plexus: a comprehensive review of its history, anatomy, function, histology, embryology, and surgical considerations. *Childs Nerv Syst*. 2014; 30(2): 205–214, doi: [10.1007/s00381-013-2326-y](https://doi.org/10.1007/s00381-013-2326-y), indexed in Pubmed: [24287511](https://pubmed.ncbi.nlm.nih.gov/24287511/).
81. Murakami T, Yasuda Y, Mita S, et al. Prealbumin gene expression during mouse development studied by in situ hybridization. *Cell Differ*. 1987; 22(1): 1–9, doi: [10.1016/0045-6039\(87\)90408-8](https://doi.org/10.1016/0045-6039(87)90408-8), indexed in Pubmed: [3690669](https://pubmed.ncbi.nlm.nih.gov/3690669/).
82. Najbrt R, Červený C, Bednář K, Mikyska E, Štarha O. *Veterinární anatomie 2. Státní zemědělské nakladatelství, Praha 1982*.
83. Neman J, Chen TC. *The choroid plexus and cerebrospinal fluid*. Academic Press, Cambridge 2016.
84. Netter FH. *Atlas der Anatomie des Menschen*. Novartis, Basel 1997.
85. Nickel R, Schummer A, Seiferle E. *Lehrbuch der Anatomie der Haustiere. 4 Nervensystem, Sinnesorgane, Endokrine Drüsen*. Parey, Berlin 1975.
86. Nickel R, Schummer A, Seiferle E. *Lehrbuch der Anatomie der Haustiere Band 4 Nervensystem, Sinnesorgane, Endokrine Drüsen*. Parey Verlag, Stuttgart 2004.
87. Nieuwenhuys R. *The Human Central Nervous System*. Springer, Berlin 2008.
88. Paulsen F, Waschke J. *Sobotta: Atlas der Anatomie: Kopf, Hals und Neuroanatomie*. Elsevier, Munich 2017.
89. Pschyrembel® *Klinisches Wörterbuch*, 260th ed. Walter de Gruyter, Berlin, New York 2004.
90. Ramraje S, Kulkarni S, Choudhury B. Paediatric intraventricular meningiomas. A report of two cases. *Australas Med J*. 2012; 5(2): 126–129, doi: [10.4066/AMJ.2012.993](https://doi.org/10.4066/AMJ.2012.993), indexed in Pubmed: [22905053](https://pubmed.ncbi.nlm.nih.gov/22905053/).
91. Redzic ZB, Segal MB. The structure of the choroid plexus and the physiology of the choroid plexus epithelium. *Adv Drug Deliv Rev*. 2004; 56(12): 1695–1716, doi: [10.1016/j.addr.2004.07.005](https://doi.org/10.1016/j.addr.2004.07.005), indexed in Pubmed: [15381330](https://pubmed.ncbi.nlm.nih.gov/15381330/).
92. Rüsse I, Sinowatz F. *Lehrbuch der Embryologie der Haustiere: 39 Tab*. Parey, Berlin 1991.
93. Sakka L, Coll G, Chazal J. Anatomy and physiology of cerebrospinal fluid. *Eur Ann Otorhinolaryngol Head Neck Dis*. 2011; 128(6): 309–316, doi: [10.1016/j.anorl.2011.03.002](https://doi.org/10.1016/j.anorl.2011.03.002), indexed in Pubmed: [22100360](https://pubmed.ncbi.nlm.nih.gov/22100360/).
94. Santos MM, Souweidane MM. Purely endoscopic resection of a choroid plexus papilloma of the third ventricle: case report. *J Neurosurg Pediatr*. 2015; 16(1): 54–57, doi: [10.3171/2014.12.PEDS14287](https://doi.org/10.3171/2014.12.PEDS14287), indexed in Pubmed: [25860986](https://pubmed.ncbi.nlm.nih.gov/25860986/).
95. Sato M, Tamura R, Morimoto Y, et al. Quiescent and activated fibroblasts in lateral ventricular meningioma with a dura-like membrane. *World Neurosurg*. 2021; 147: e215–e224, doi: [10.1016/j.wneu.2020.12.025](https://doi.org/10.1016/j.wneu.2020.12.025), indexed in Pubmed: [33316485](https://pubmed.ncbi.nlm.nih.gov/33316485/).
96. Simić V. *Nervni sistem i čula domaćih sisara*. Veterinarski fakultet: Savez veterinara i veterinarskih tehničara. Beograd, Belgrad 1991.
97. Sisson S. *The anatomy of the domestic animals*. Saunders, Philadelphia 1953.
98. Spierer R. The debated neuroanatomy of the fourth ventricle. *J Anat*. 2023; 243(4): 555–563, doi: [10.1111/joa.13885](https://doi.org/10.1111/joa.13885), indexed in Pubmed: [37170923](https://pubmed.ncbi.nlm.nih.gov/37170923/).
99. Spoerri O, Alexy HJ. The subfornical organ in murine hydrocephalus: a light-microscopic study. *Dev Med Child Neurol*. 1974; 16(6 Suppl 32): 91–94, doi: [10.1111/j.1469-8749.1974.tb03455.x](https://doi.org/10.1111/j.1469-8749.1974.tb03455.x), indexed in Pubmed: [4475653](https://pubmed.ncbi.nlm.nih.gov/4475653/).
100. Steinemann A, Galm I, Chip S, et al. Claudin-1, -2 and -3 Are Selectively Expressed in the Epithelia of the Choroid Plexus of the Mouse from Early Development and into Adulthood While Claudin-5 is Restricted to Endothelial Cells. *Front Neuroanat*. 2016; 10: 16, doi: [10.3389/fnana.2016.00016](https://doi.org/10.3389/fnana.2016.00016), indexed in Pubmed: [26941614](https://pubmed.ncbi.nlm.nih.gov/26941614/).
101. Stoffel MH. *Funktionelle Neuroanatomie für die Tiermedizin*. Enke, Stuttgart 2011.
102. Strong LH. The vascular and ependymal development of the early stages of the tela choroidea of the lateral ventricle of the mammal. *J Morphol*. 1964; 114: 59–82, doi: [10.1002/jmor.1051140104](https://doi.org/10.1002/jmor.1051140104), indexed in Pubmed: [14114963](https://pubmed.ncbi.nlm.nih.gov/14114963/).
103. Swetloff A, Ferretti P. Changes in E2F5 intracellular localization in mouse and human choroid plexus epithelium with development. *Int J Dev Biol*. 2005; 49(7): 859–865, doi: [10.1387/ijdb.051996as](https://doi.org/10.1387/ijdb.051996as), indexed in Pubmed: [16172982](https://pubmed.ncbi.nlm.nih.gov/16172982/).
104. Testut L, Latarjet A. *Traite D'Anatomie Humaine: Anatomie Descript: Angéiologie - Névrologie*. G. Doin & Cie, Paris 1948.
105. Tubbs RS, Louis RG, Wartmann CT, et al. The velum interpositum revisited and redefined. *Surg Radiol Anat*. 2008; 30(2): 131–135, doi: [10.1007/s00276-007-0293-2](https://doi.org/10.1007/s00276-007-0293-2), indexed in Pubmed: [18094919](https://pubmed.ncbi.nlm.nih.gov/18094919/).
106. Waldeyer A, Mayet A. *Anatomie des Menschen 2: Kopf und Hals, Auge, Ohr, Gehirn, Arm, Brust*. Walter De Gruyter, Berlin 1976.
107. Wen HT, Rhoton AL, de Oliveira E. Transchoroidal approach to the third ventricle: an anatomic study of the choroidal

- fissure and its clinical application. *Neurosurgery*. 1998; 42(6): 1205–17; discussion 1217, doi: [10.1097/00006123-199806000-00001](https://doi.org/10.1097/00006123-199806000-00001), indexed in Pubmed: [9632178](https://pubmed.ncbi.nlm.nih.gov/9632178/).
108. Whitehead MT, Vezina G, Schlatterer SD, et al. Taenia-tela choroidea complex and choroid plexus location help distinguish Dandy-Walker malformation and Blake pouch cysts. *Pediatr Radiol*. 2021; 51(8): 1457–1470, doi: [10.1007/s00247-021-04991-3](https://doi.org/10.1007/s00247-021-04991-3), indexed in Pubmed: [33783580](https://pubmed.ncbi.nlm.nih.gov/33783580/).
109. Wolfram-Gabel R, Maillot C, Koritke JG, et al. The vascular patterns in choroid tela of the third ventricle in man. *Arch Anat Histol Embryol*. 1984; 67: 3–42.
110. Wolfram-Gabel R, Maillot C, Koritké JG, et al. La vascularisation de la toile choroïdienne du ventricule latéral chez l'homme. *Cells Tissues Organs*. 2008; 128(4): 301–321, doi: [10.1159/000146358](https://doi.org/10.1159/000146358).
111. World Association of Veterinary Anatomists. *Nomina Anatomica Veterinaria*, 2017. <https://www.wava-amav.org/wava-documents.html> (20.04.2023).
112. Wu J, Zhou M, Qin K, et al. Microscopic anatomical atlas study on the lateral ventricles of the rabbit cerebrum and its related structures. *Translat Res Anat*. 2021; 25: 100140, doi: [10.1016/j.tria.2021.100140](https://doi.org/10.1016/j.tria.2021.100140).