


CASE REPORT

Companion or pet animals

Successful treatment of a Himalayan cat with feline orofacial pain syndrome

Katrin Ertelt¹  | Judith Dörner²¹Anaesthesia and Perioperative Intensive Care Unit, Department of Small Animals and Horses, University of Veterinary Medicine, Vienna, Austria²Small Animal Surgery, Department of Small Animals and Horses, University of Veterinary Medicine, Vienna, Austria

Correspondence

Katrin Ertelt, Anaesthesia and Perioperative Intensive Care Unit, Department of Small Animals and Horses, University of Veterinary Medicine, Vienna, Austria.

Email: katrin.ertelt@vetmeduni.ac.at

Abstract

Feline orofacial pain syndrome is a neuropathic pain disorder in cats, characterised by oral discomfort and tongue self-mutilation. The pathogenesis of feline orofacial pain syndrome remains unclear, but trigger factors such as dental disease and environmental stress have been described. Feline orofacial pain syndrome is a diagnosis of exclusion, and suggested treatment includes administration of non-steroidal anti-inflammatory agents, opioids and adjuvant drugs for analgesia. This case report describes a 4-year-old female Himalayan cat with anorexia, ranula and unilateral lesions of the tongue. Clinical signs ranged from pawing at the mouth to tongue self-mutilation during severe pain attacks. Although no dental disease was present, a dominant and suppressive partner cat may have had a stressful influence. First-line treatment with non-steroidal anti-inflammatory drugs and opioids could not prevent further pain attacks. Successful treatment was achieved with administration of pregabalin and minimisation of potential stress factors. No clinical signs of pain were observed in a follow-up period of 2 years.

BACKGROUND

Feline orofacial pain syndrome (FOPS) is a poorly understood pain condition, characterised by severe oral discomfort.^{1,2} Burmese cats are the most frequently affected breed; however, FOPS has also been reported in Siamese and crossbred cats.³

The pathogenesis of the disease remains unclear, and information regarding the topic is scarce within veterinary literature. However, several factors have been associated with triggering of the disease. In young animals, FOPS is commonly associated with eruption of permanent teeth, and signs are usually self-limiting. Conversely, in adult cats, periodontal disease constitutes the main predisposing factor.^{3,4} Rarely, oral disease may evolve to neurogenic inflammation of the trigeminal ganglion, potentially developing into a maladaptive pain syndrome.² A stressful environment has been also proposed as a factor affecting the expression of the disease. It is reported that cats with poor social coping strategies or cats in multi-cat households may be especially vulnerable.³

Affected cats can present signs of pain in acute and severe, or in chronic and episodic, forms.² Pain seems to originate in only one side of the oral cavity.² Clinical signs include excessive licking, chewing, salivation and pawing at the mouth.^{1,3} In severe cases, cats can self-mutilate their tongue and buccal mucosa, which leads to anorexia.³

As affected cats often present unremarkable neurological and clinical examinations, diagnosis of FOPS is made by

exclusion of other possible causes of orofacial pain (e.g., tooth resorption, periodontal disease, gingivitis, oral neoplasia, eosinophilic granuloma) or trigeminal nerve dysfunction.⁴ The lack of positive response to traditional analgesics may also contribute to the diagnosis of FOPS. Based on anecdotal information, the most useful adjuvant drugs for analgesia for treating FOPS are gabapentinoids (gabapentin or pregabalin) or phenobarbital.² Ultimately, the syndrome can be recurrent, but may also be resistant to any treatment.

Unfortunately, only a limited number of published reports on FOPS (e.g., treatment protocols) is available. Therefore, the aim of this case report is to describe the clinical presentation, management and outcome of a 4-year-old Himalayan cat diagnosed with FOPS, and to discuss a yet unreported treatment that may have favoured a successful outcome.

CASE PRESENTATION

A 4-year-old, female, entire Himalayan cat, weighing 4 kg, was presented to the Surgical Unit of the Veterinary Medicine University Vienna with a history of anorexia for 2 days and mild gingivitis at the maxillary teeth and sublingual unilateral swelling. The cat lived in the same household with another male neutered cat. According to the owner, the cat normally had an anxious temperament.

This is an open access article under the terms of the [Creative Commons Attribution](https://creativecommons.org/licenses/by/4.0/) License, which permits use, distribution and reproduction in any medium, provided the original work is properly cited.

© 2024 The Author(s). *Veterinary Record Case Reports* published by John Wiley & Sons Ltd on behalf of British Veterinary Association.

INVESTIGATIONS

General physical examination was unremarkable, except for the presence of a fluid-filled soft mass on the right ventral surface of the tongue, and additionally a wound (2 × 7 mm) on the right caudal aspect of the tongue, surrounded by inflamed tissue and white spots. A presumptive diagnosis of a ranula was made with a separated wound on the caudal aspect of the tongue. First-line treatment included administration of meloxicam (0.05 mg/kg orally, once daily [SID], Metacam, Boehringer Ingelheim) for 5 days, supportive care and syringe feeding by the owner.

Four days later, the cat was presented again for ongoing anorexia. Syringe feeding was difficult for the owners as the cat was reluctant to swallow. The ranula had decreased in size, but the lesion on the caudal side of the tongue was still present. To ensure food intake and to favour wound healing, an oesophageal tube was placed under general anaesthesia. After 5 days of oesophageal feeding, the cat began to eat, and 5 days later, the oesophageal feeding tube was removed. The ranula was no longer present, and the lesion on the tongue appeared to be completely healed. The cat was then discharged.

Seven weeks later, the cat was presented again with signs of anorexia, swelling on the lateral right side of the tongue and abnormal tongue movements. On examination of the oral cavity, necrosis and tissue inflammation on the right caudal aspect of the tongue were observed (Figure 1). The evaluation of blood and serum biochemistry was carried out and all parameters were within normal limits, except for eosinophilia (1534/μL, reference: <800/μL). Under general anaesthesia, an excisional biopsy of the lingual tissue and marsupialisation of the ranula were performed to determine the presence of neoplasia or eosinophilic granuloma (Figure 2). Additionally, the sample was submitted for culture and antibiogram. Subsequently, an oesophageal tube was placed. Histopathology of the retrieved sample revealed a fibrinous and purulent glossitis with bacterial involvement of *Fusobacterium necrophorum* and *Pasteurella multocida*. Treatment consisted of meloxicam (0.05 mg/kg, SID) and amoxicillin-clavulanic acid (22 mg/kg twice a day [BID], Kesium 40 mg/10 mg Ceva Tiergesundheit), both administered through the oesophageal feeding tube. The lesions healed, and no further pain episodes occurred.

Five days later, the cat showed excessive chewing and licking of the mouth and tongue. Because of multiple biting lesions on the tongue, the route of treatment was changed and therefore amoxicillin-clavulanic acid and meloxicam were given intravenously for the subsequent 7 days. Because of the severity of the lesions (Figures 3 and 4), buprenorphine (15 μg/kg intravenously four times a day [QID]; Bupaq 0.3 mL/mL, Richterpharma) was administered. Topical administration of 1 mg/kg of lidocaine gel (Xylanaest purum 2%, Gebro Pharma) resulted in aggressive reactions, and therefore, this and other further oral treatments or manipulation were discontinued. However, the case progressed to self-mutilation of the tongue. Another general anaesthetic procedure was performed in order to surgically clean and suture the self-inflicted lingual lesion. Additionally, a thorough dental examination as well as dental radiographs were performed to investigate the presence of dental disease as a possible source of oral pain. Dental radiographs were unremarkable, and the cat recovered well

LEARNING POINTS/TAKE-HOME MESSAGES

- Feline orofacial pain syndrome is a condition of neuropathic pain, which is characterised by behavioural signs of severe oral discomfort.
- Cats show pawing at the mouth and excessive licking and chewing movements, typically on one side. In more severe cases, tongue or buccal mucosa self-mutilation can occur.
- Attacks can be triggered by mouth movements (while eating or grooming), painful teeth conditions like teething, periodontitis or tooth resorptions, as well as stressful environments (multi-cat households or no areas of retreat).
- There is no specific diagnostic test for feline orofacial pain syndrome. Diagnosis is made on the basis of typical behavioural signs, exclusion of other explanations or diseases.
- Cats usually do not respond to traditional analgesic treatment (non-steroidal anti-inflammatory drugs, opioids), and adjuvant pain therapy (gabapentin, phenobarbital) should be used. In this case, pregabalin was successfully applied as single therapy. In addition to medication, elimination of environmental stressors might be necessary to achieve successful treatment.

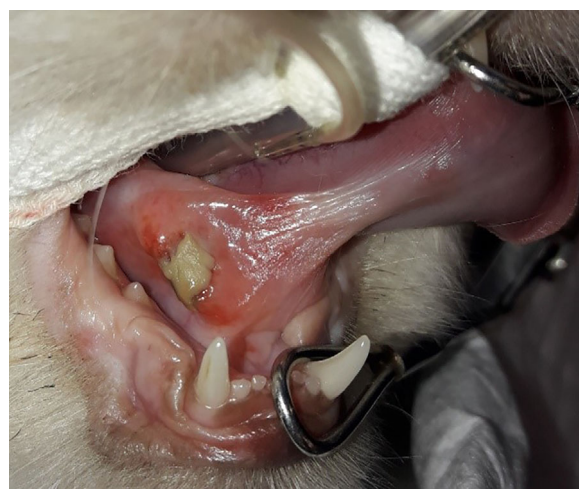


FIGURE 1 A 4-year-old female Himalayan cat that presented a necrotic wound on the right caudal aspect of the tongue. In this case, no obvious reasons (e.g., dental disease) for the oral discomfort could be found. First-line treatment with non-steroidal anti-inflammatory drugs and opioids could not prevent further pain attacks. Successful treatment via administration of pregabalin and minimisation of potential stress factors was achieved, and a diagnosis by exclusion of feline orofacial pain syndrome was made.

from general anaesthesia. In the following days, no further pain episodes occurred, the cat started eating and the feeding tube was removed. Antimicrobial and analgesic drugs were stopped. The cat was discharged 3 days postoperatively with pregabalin (4 mg/kg BID per os; Pregabalin Sandoz, 25 mg).

Considering the recurrent signs of oral discomfort, the partial response to treatment, the potential stressful envi-

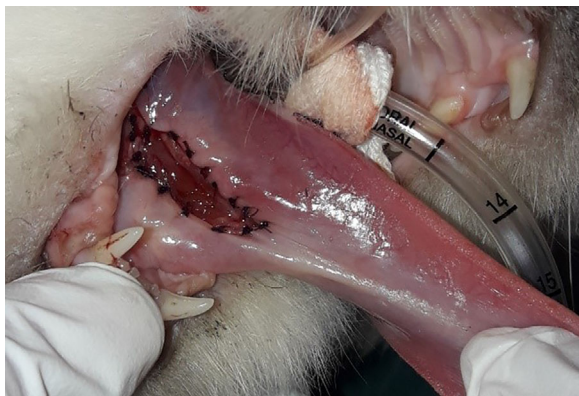

FIGURE 2 Marsupialisation after debridement of the wound in the 4-year-old female Himalayan cat. Additionally, an excision of necrotic tissue was made.

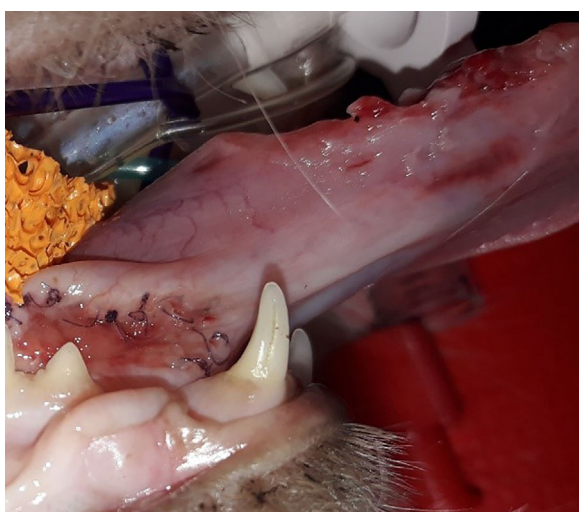


FIGURE 3 Healing of the marsupialisation side on the caudal aspect of the tongue. On the right ridge of the tongue, injuries of self-mutilation can be observed.

ronment of the cat (probable oppression from the other cat in the household), the predisposed breed and the exclusion of other diseases, a presumptive diagnosis of FOPS was made.

DIFFERENTIAL DIAGNOSIS

Differential diagnosis of a painful oral condition included dental and periodontal diseases (e.g., tooth resorption, tooth fracture, periodontal disease, gingivitis, stomatitis), presence of an oral foreign body, oral neoplasia, eosinophilic granuloma or a ranula.

Thorough examination of the oral cavity allowed to exclude the presence of a foreign body. No abnormalities were detected upon clinical and radiological examination of the teeth, and therefore, teeth disease as the cause of pain was discarded. Biopsy and histological examination of the tissue sample allowed to exclude other causes of pain such as eosinophilic granuloma, neoplasia or ranula.

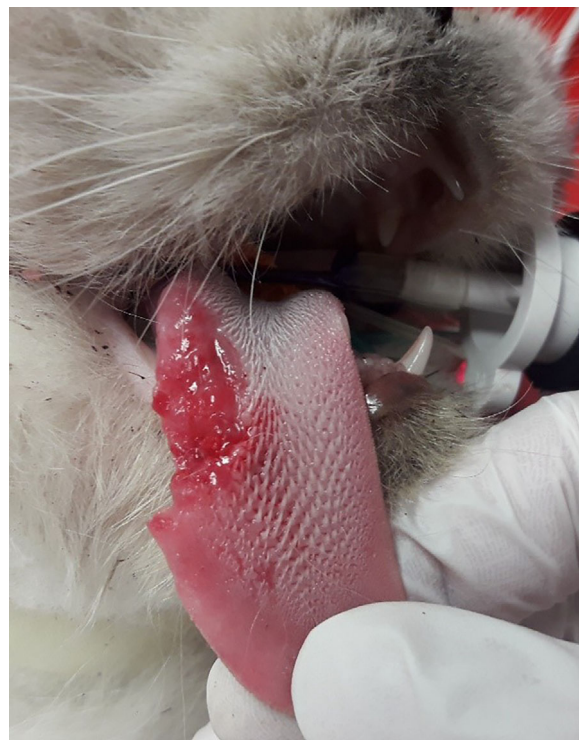

FIGURE 4 Self-mutilation of the tongue. Severe unilateral bite wounds and tissue loss can be observed. In severe cases like this, cats may be fed via oesophageal feeding tube until full recovery.

TREATMENT

Considering the tentative diagnose of FOPS, treatment with pregabalin (4 mg/kg BID per os; Pregabalin Sandoz, 25 mg) was started. Additionally, the owner was advised to remove the cat from any potential stressors and maintain a comfortable environment.

OUTCOME AND FOLLOW-UP

The clinical condition of the cat improved during the first week after discharge. It was active, less anxious, food intake was normal, and it showed no signs of oral pain.

However, on the eighth day the cat showed severe signs of oral pain, which included excessive licking and pawing of the mouth. Upon presentation in the clinic and subsequent clinical examination, no abnormalities or further injuries in the oral cavity could be detected. The previous lesion on the tongue seemed to be healing (Figure 5). Due to the severity of the painful episode, phenobarbital (2.5 mg/kg BID per os, Phenoleptil, Dechra Veterinary Products) was indicated in addition to the ongoing treatment with pregabalin. Phenobarbital was titrated down and eventually discontinued after 1 week. The cat seemed comfortable, and normal feed intake resumed.

Due to stress behaviours exhibited during heat, spaying of the animal was indicated. The surgical procedure was performed 6 weeks later under general anaesthesia. During the same anaesthetic procedure, further clinical and radiological examination of the mouth were performed and showed no abnormalities, except for mild gingivitis.

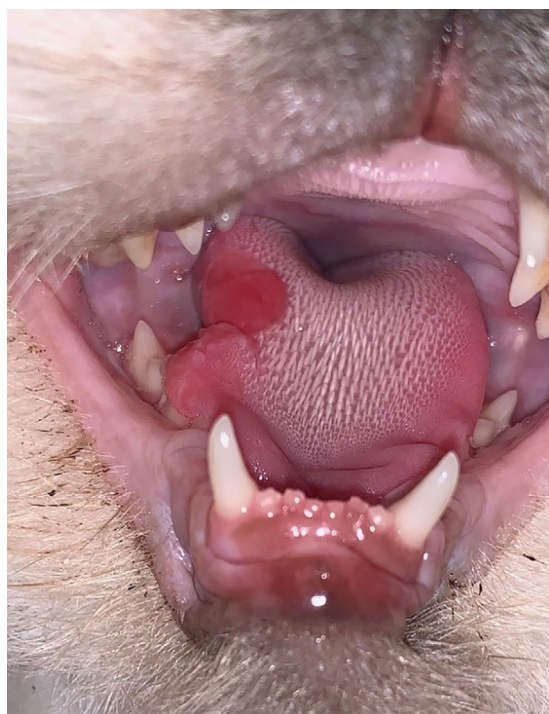

FIGURE 5 After surgical repair and healing of the tongue wound (3 weeks after attack), the pain was managed with pregabalin (2.5 mg/kg twice a day). With this dosage, the cat was able to maintain a normal eating pattern, and remained comfortable without signs of pain for the following 2 years.

Further 3- and 8-month follow-up periods revealed a favourable progression without pain episodes and a 500 g increase in bodyweight. Pregabalin dose was reduced to 2 mg/kg BID for the next weeks. However, due to a communication error, the owner kept on reducing the dose of pregabalin every other day for 5 days and eventually discontinued the administration. Then, the cat showed again progressing discomfort in the mouth together with licking and excessive tongue movements, which seemed to be originated on the right aspect of the tongue. Five days after pregabalin administration was stopped, there was a new severe pain episode, characterised by chewing on the tongue and pawing the mouth and minimal oral bleeding in the mouth. Therefore, pregabalin administration was resumed and further increased to 3 mg/kg BID for 8 weeks, and then reduced to 2.5 mg/kg BID. With this dosage, the cat was able to maintain a normal eating pattern, and remained comfortable without signs of pain for the following 2 years. The owner was told to contact the referral veterinarian for a follow-up blood check every 6–12 months. No deviation on blood parameters has been observed so far.

DISCUSSION

The diagnosis and management of FOPS in a cat is described, highlighting the importance of pregabalin as an adjuvant treatment.

FOPS is considered a neuropathic pain disorder, which is caused by a lesion or disease of the somatosensory nervous system.⁴ It is a rare condition with a major impact on patient's

quality of life. As with other neuropathic pain disorders, diagnosis and treatment are difficult.

Direct nerve injury is thought to result in ongoing stimulation of the dorsal horn resulting from excessive firing of C-fibres, stimulation of *N*-methyl-D-aspartate receptors and the development of new sympathetic nerve fibres.⁵ This ongoing stimulation influences higher neural centres with respect to recognition of sensation and pain, leading to excessive pain conditions such as allodynia or hyperpathia.⁶ This state of neuropathic pain provides no benefit to the animal and is a disease in itself.

As reported in this case, during FOPS the discomfort is limited to the oral and buccal cavity. The trigeminal nerve provides sensory innervation not only to this area, but also to the orbital region via the ophthalmic branch, to the maxillary region via the maxillary branch, and to the mandibular region and tongue via the mandibular branch. In FOPS, no obvious discomfort on other head regions (e.g., nose and eyes) are normally observed.

FOPS has been compared to neuropathic pain disorders in humans, such as trigeminal neuralgia and glossodynia.^{4,7} In human medicine, trigeminal neuralgia is a rare, unilateral, episodic pain in the face that is reported as electric shock-like pain attack. It can be provoked by light touch to the face, eating, cold winds or vibrations.⁸ Likewise, in all described cases of FOPS, the discomfort was characterised as unilateral or worse on one side,^{3,4} which was comparable to the signs of unilateral pain observed in this case. In a case series of 113 FOPS cats, the authors hypothesised that cats prone to FOPS may have a dysfunction of central and/or ganglion processing of sensory trigeminal information.³ Signs of FOPS seem to occur when the endings of the trigeminal nerves are sensitised, such as during teething or in the presence of dental disease. The same study found that 63% of the cats had oral lesions, including dental disease, oral ulceration or eruption of permanent teeth.³ However, the cat in this case report underwent a dental evaluation, but no dental diseases, except mild gingivitis, were detected. A ranula was diagnosed, but it remains unclear whether it caused the symptoms or if it appeared as a result of self-mutilation.

A more unusual human facial pain syndrome, which is part of the spectrum of trigeminal neuralgia, is glossodynia,⁹ which is also known as burning mouth syndrome. It is characterised by a burning or prickling painful sensation of the oral mucosa that most commonly involves the tongue in the absence of physical abnormalities of the oral mucosa.⁷ This may be comparable to the symptoms present in this cat. As reported by Rusbridge et al.³, all of the affected cats with FOPS show caudal tongue discomfort, which seems to be the primary problem. Additionally, many cats can also be presented with mutilation injuries of the tongue. In comparison to trigeminal neuralgia, the cause of glossodynia is not known and most cases are described as 'idiopathic'. Psychological factors, such as anxiety, depression and phobias, have been reported to play a significant role at the beginning, although this may more be the effect rather than the cause of this pain disease.¹⁰

Further diagnostic imaging techniques (i.e., magnetic resonance imaging) are indicated if the animal presents neurological deficits, especially those associated with the trigeminal nerve.² Although often unremarkable, they could be helpful to discard abnormalities in the nerve endings or compression

of the trigeminal nerve. This diagnostic tool was not available in this case.

Stress seemed to be a trigger factor in the case presented here. Events such as cat shows and veterinary hospital visits, or changes in the household (death of the primary carer or renovations) have been additionally named as triggers for FOPS events.^{3,4} The owner described the cat as anxious and shy and frequently suppressed by the male cat in the household. Every time the cat was in heat, it showed anxious and stressed behaviour. To ameliorate this stress factor, the cat was spayed. Additionally, the owner stated that the cat was very sensitive to any change in the living circumstances, such as visitors, unfamiliar noises or the absence of owners. The owners were advised to reduce any possible cause of stress, and to separate the cats if the male cat behaved very dominant.

Neuropathic pain is a great challenge for clinicians, as it is not predictable, it may vary between individuals, and the severity of symptoms may fluctuate over time. Generally, this type of pain responds poorly to traditional analgesics or to standard doses of drugs. Anticonvulsant drugs, especially barbiturates and gabapentinoids, are used for the treatment of neuropathic pain.² They are reported in human patients to be particularly effective for burning and lancinating pain.¹¹ In the literature, cats with FOPS have been successfully treated with the non-steroidal anti-inflammatory agents, phenobarbital, gabapentin and amitriptyline.^{3,12} It is recommended that licenced analgesics are used first, but if ineffective, a switch to drugs for treatment of neuropathic pain can follow.

As the authors have had good success with pregabalin and have little experience with phenobarbital or amitriptyline, pregabalin was used for initial therapy.

Gabapentin and pregabalin are drugs that were originally used for anticonvulsant therapy, and in recent years also for neuropathic pain, including the management of trigeminal neuralgia in humans.^{13,14} Both drugs influence the pain pathway by preventing the release of the excitatory neurotransmitter glutamate in the dorsal horn via interaction with the $\alpha 2$ delta subunit of voltage-gated calcium channels.^{14,15} Pregabalin has been shown to be effective and well-tolerated for the management of neuropathic pain, fibromyalgia, peripheral neuropathy¹⁶ and generalised anxiety disorders in humans.¹⁷ Pharmacokinetic studies of pregabalin in cats demonstrate rapid absorption, linear pharmacokinetics and high oral bioavailability, with a high therapeutic index after oral administration.^{18,19} Additionally, a mild sedative effect has been reported. In this case, sedation was deemed beneficial, and therefore treatment was initiated with the higher dose range (3.95 mg/kg BID). Unlike gabapentin, which requires higher doses and more frequent administration (i.e., 5–25 mg/kg BID–QID), the dosage and less frequent administration of pregabalin may result in better owner compliance.

Phenobarbital, a therapeutic with well-documented pharmacokinetics in the cat,²⁰ has been demonstrated to be effective in the treatment of FOPS cases. Treatment would have been indicated in this case if pain episodes were refractory to pregabalin treatment.² Phenobarbital enhances synaptic inhibition by interacting with the gamma-aminobutyric acid (GABA) receptor and inhibiting voltage-activated sodium and calcium channels.²¹ GABAergic neurons and GABA receptors are found in the dorsal horn²² and trigeminal ganglion,²³

where they control the propagation of pain signals from the periphery to higher central nervous system areas.^{6,24} Recent evidence in laboratory mice indicates that diminished GABA-mediated inhibitory control is a major factor in chronic pain syndromes.²² Clinical and experimental data indicate that changes in the expression of voltage-gated sodium channels in trigeminal ganglia play a key role in the pathogenesis of trigeminal neuralgia and that drugs that antagonise these channels are potentially therapeutic.^{25–28}

A diagnosis of exclusion of FOPS was based on the clinical signs of unilateral severe oral discomfort, repeated pain episodes in a period of several weeks, self-mutilation, no response of traditional analgesics and the successful treatment of neuropathic pain with pregabalin.

Remission of clinical signs was observed relatively early during treatment with pregabalin. Reduction of stress could have also played a role in the management of this case. However, further studies are necessary to establish effective drug protocols and optimal management for treating this disease.

AUTHOR CONTRIBUTIONS

Case management, investigation, writing and reviewing the manuscript: Katrin Ertelt and Judith Dörner.

CONFLICT OF INTEREST STATEMENT

The authors declare they have no conflicts of interest.

FUNDING INFORMATION

The authors received no specific funding for this work.

ETHICS STATEMENT

The authors declare to have strictly adhered to the good scientific practice standards implemented by the University of Veterinary Medicine, Vienna, Austria. Furthermore, for all diagnostic and therapeutic procedures, an informed consent of the owner was obtained.

ORCID

Katrin Ertelt  <https://orcid.org/0009-0002-7405-5867>

REFERENCES

- Monteiro B, Lascelles D. Assessment and recognition of chronic (maladaptive) pain. In: Steagall P, Robertson S, Taylor P, editors. *Feline anesthesia and pain management*. Hoboken NJ: John Wiley & Sons; 2018. p. 241–56.
- Rusbridge C. Neurobehavioral disorders: the corticolimbic system in health and disease. *Vet Clin North Am Small Animal Pract*. 2020;50(5):1157–81.
- Rusbridge C, Heath S, Gunn-Moore DA, Knowler SP, Johnston N, McFadyen AK. Feline orofacial pain syndrome (FOPS): a retrospective study of 113 cases. *J Feline Med Surg*. 2010;12(6):498–508.
- Rusbridge C, Heath S. Feline orofacial pain syndrome. In: Rodan I, Heath S, editors. *Feline behavioral health and welfare*. St Louis, MO: Elsevier; 2016. p. 213–26.
- Woolf CJ, Thompson SWN. The induction and maintenance of central sensitization is dependent on N-methyl-D-aspartic acid receptor activation: implications for the treatment of post-injury pain hypersensitivity states. *Pain*. 1991;44(3):293–99.
- O'Hagan B. Neuropathic pain in a cat post-amputation. *Aust Vet J*. 2006;84(3):83–86.
- Crow HC, Gonzalez Y. Burning mouth syndrome. *Oral Maxil Surg Clin*. 2013;25(1):67–76.
- Zakrzewska JM, Linskey ME. Trigeminal neuralgia. *BMJ*. 2014;348:g474.
- Marbach JJ. Medically unexplained chronic orofacial pain. Temporomandibular pain and dysfunction syndrome, orofacial phantom pain,

- burning mouth syndrome and trigeminal neuralgia. *Med Clin North Am.* 1999;83:691–710.
10. Trikkas G, Nikolatou O, Samara C, Bazopoulou-Kyrkanidou E, Rabavilas AD, Christodoulou GN. Glossodynia: personality characteristics and psychopathology. *Psychother Psychosom.* 1996;65(3):163–68.
 11. Costigan M, Woolf CJ. Pain: molecular mechanisms. *J Pain.* 2000;1(3):35–44.
 12. Monteiro B, Troncy E. Treatment of chronic (maladaptive) pain. In: Steagall P, Robertson S, Taylor P, editors. *Feline anesthesia and pain management.* Hoboken NJ: John Wiley & Sons; 2018. p. 257–80.
 13. Obermann M, Yoon M, Sensen K, Maschke M, Diener H, Katsarava Z. Efficacy of pregabalin in the treatment of trigeminal neuralgia. *Cephalalgia.* 2007;28(2):174–81.
 14. Figueroa RG, Juyo AE, García GC, Castillo IPB. [The effect of gabapentin in bucco-facial allodynia. Experimental correlation of the trigeminal nerve.] Efecto de la gabapentina en la alodinia buco-facial. Correlación experimental de neuralgia trigeminal. *Rev Neurol.* 1999;29(12):1147–53.
 15. Krafft RM. Trigeminal neuralgia. *Am Fam Physician.* 2008;77:1291–96.
 16. Freynhagen R, Strojek K, Griesing T, Whalen E, Balkenohl M. Efficacy of pregabalin in neuropathic pain evaluated in a 12-week, randomised, double-blind, multicentre, placebo-controlled trial of flexible- and fixed-dose regimens. *Pain.* 2005;115(3):254–63.
 17. Pande AC, Crockatt JG, Feltner DE, Janney CA, Smith WT, Weisler R, et al. Pregabalin in generalized anxiety disorder: a placebo-controlled trial. *Am J Psychiatry.* 2003;160(3):533–40.
 18. Esteban MA, Dewey CW, Schwark WS, Rishniw M, Boothe DM. Pharmacokinetics of single-dose oral pregabalin administration in normal cats. *Front Vet Sci.* 2018;5:136.
 19. Lamminen T, Doedée A, Hyttälä-Hopponen M, Kaskinoro J. Pharmacokinetics of single and repeated oral doses of pregabalin oral solution formulation in cats. *J Vet Pharmacol Ther.* 2022;45(4):385–91.
 20. Cochrane SM, Parent JM, Black WD, Allen DG, Lumsden JH. Pharmacokinetics of phenobarbital in the cat following multiple oral administration. *Can J Vet Res.* 1990;54(3):309–12.
 21. Smith MD, Metcalf CS, Wilcox KS. Pharmacotherapy of the epilepsies. In: Brunton LL, Hilal-Dandan R, Knollmann BC, editors. *Goodman & Gilman's the pharmacological basis of therapeutics.* McGraw Hill Education; 2018. p. 303–26.
 22. Zeilhofer HU, Möhler H, Lio AD. GABAergic analgesia: new insights from mutant mice and subtype-selective agonists. *Trends Pharmacol Sci.* 2009;30(8):397–402.
 23. Hayasaki H, Sohma Y, Kanbara K, Maemura K, Kubota T, Watanabe M. A local GABAergic system within rat trigeminal ganglion cells. *Eur J Neurosci.* 2006;23(3):745–57.
 24. Price TJ, Hargreaves KM, Cervero F. Protein expression and mRNA cellular distribution of the NKCC1 cotransporter in the dorsal root and trigeminal ganglia of the rat. *Brain Res.* 2006;1112(1):146–58.
 25. Tremont-Lukats IW, Megeff C, Backonja MM. Anticonvulsants for neuropathic pain syndromes. *Drugs.* 2000;60(5):1029–52.
 26. Wood JN, Boorman JP, Okuse K, Baker MD. Voltage-gated sodium channels and pain pathways. *J Neurobiol.* 2004;61(1):55–71.
 27. Amir R, Argoff CE, Bennett GJ, Cummins TR, Durieux ME, Gerner P, et al. The role of sodium channels in chronic inflammatory and neuropathic pain. *J Pain.* 2006;7(5):S1–29.
 28. Prasad S, Galetta S. Trigeminal neuralgia. *Neurologist.* 2009;15(2):87–94.

How to cite this article: Ertelt K, Dörner J. Successful treatment of a Himalayan cat with feline orofacial pain syndrome. *Vet Rec Case Rep.* 2024;e949.
<https://doi.org/10.1002/vrc2.949>

IMAGE QUIZ

A severely injured tongue of a cat, with multiple bite and chewing lesions on the right ridge. A small area of tissue loss can be observed (Figure 4).

MULTIPLE-CHOICE QUESTION

What is the likely diagnosis?

POSSIBLE ANSWERS TO MULTIPLE-CHOICE QUESTION

1. Tongue injury after biting an electric cord.
2. Squamous cell carcinoma of the tongue.
3. Self-mutilation of the tongue in the course of a pain attack of feline orofacial pain syndrome.
4. Eosinophilic granuloma.

CORRECT ANSWER

3. Self-mutilation of the tongue in the course of a pain attack of feline orofacial pain syndrome.

Feline orofacial pain syndrome is a neurological disease that courses with severe pain attacks, which can lead to self-mutilation of the tongue. Lesions of the tongue are commonly unilateral.