

Protein Expression of Folate Receptor Alpha in Adenoid Cystic Carcinoma of the Head and Neck

Julia Schnoell¹, Bernhard J Jank¹, Lorenz Kadletz-Wanke¹, Stefan Stoiber^{2,3}, Elisabeth Gurnhofer², Michaela Schleder², Gregor Heiduschka^{1,*}, Lukas Kenner^{2-5,*}

¹Department of Otorhinolaryngology, Head and Neck Surgery, Medical University of Vienna, Vienna, 1090, Austria; ²Department of Pathology, Medical University of Vienna, Vienna, Austria; ³Christian Doppler Laboratory for Applied Metabolomics, Vienna, Austria; ⁴Unit of Laboratory Animal Pathology, University of Veterinary Medicine, Vienna, Austria; ⁵CBmed GmbH - Center for Biomarker Research in Medicine, Graz, Styria, Austria

*These authors contributed equally to this work

Correspondence: Lukas Kenner, Department of Experimental Pathology and Laboratory Animal Pathology, Medical University and University of Veterinary Medicine, Vienna Waehringer Guertel 18-20, Vienna, A-1090, Austria, Tel +43 1 40400 51720, Email lukas.kenner@meduniwien.ac.at

Purpose: Folate receptor alpha (FR α) is overexpressed in various cancer entities while expression in normal tissue is limited. Thus, FR α is an attractive target in cancer therapy. Currently, various therapeutic and diagnostic approaches are under investigation in clinical trials. The aim of this study was to assess the expression and clinical relevance of FR α in adenoid cystic carcinoma of the head and neck.

Patients and Methods: In this retrospective cohort study, 43 patients with adenoid cystic carcinoma (ACC) of the head and neck were included. FR α expression was analyzed in tumor tissue and tumor-free margin in a tissue microarray using immunohistochemical staining. Protein levels were correlated with clinical parameters.

Results: FR α staining was positive in 47% of ACC patients. The tumor-free margin was positive in 22%. Patients with positive tumor tissue showed positive margin staining in 55%. FR α expression was not associated with the clinical parameters (sex, age, staging, grading, perineural invasion, lymphovascular invasion).

Conclusion: FR α expression is common in ACC of the head and neck. Therefore, FR α should be further evaluated as a therapeutic target in ACC.

Keywords: folate receptor alpha, adenoid cystic carcinoma, prognosis, targeted therapy, head and neck

Introduction

Adenoid cystic carcinoma (ACC) of the head and neck accounts for 1% of all head and neck carcinomas and 20% of salivary gland malignancies. It annually affects up to 4.5 new patients per million. While the short-term outcome is favorable, the disease is characterized by late recurrences and distant metastasis. Mainstay of treatment is surgical resection and postoperative radiotherapy. Treatment options of recurrent and metastatic disease are limited as response rates to chemotherapy are poor. Therefore, chemotherapy is reserved for rapid progression or symptomatic disease. The rare nature of the disease makes the investigation of new therapeutic targets difficult. Among various investigated therapies, only targeting MYB and NOTCH1 seem promising. Therefore, investigation of new therapeutic targets is crucial to overcome therapeutic limitations of recurrent and progressive ACC of the head and neck.¹⁻⁴

Folate is essential for DNA synthesis, repair and methylation. The uptake into cells is mediated by three transport mechanisms: The main transport is via the reduced folate carrier (RFC), followed by the proton-coupled folate transporter (PCFT) and the folate receptors. While RFC is ubiquitously expressed, PCFT is mainly responsible for the intestinal folate uptake. Among the folate receptors, the folate receptor alpha (FR α) is the most interesting for cancer treatment. FR α is a membranous glycoprotein and facilitates folate uptake via endocytosis of the folate-bound receptor.⁵⁻⁷ While expression in normal tissue is rare, FR α is commonly found in cancers, such as lung adenocarcinoma, breast and ovarian cancer.⁸⁻¹² The prognostic role of FR α in cancer is controversial since it is linked to a better and worse prognosis depending on the

cancer type.^{10,11,13} Currently, a plethora of targeted therapies against FR α are under evaluation in clinical trials in various cancers (phase I–III).^{7,14–18} Additionally, different approaches to use FR α as a diagnostic imaging tool are being investigated.^{5–7}

The aim of this study was to evaluate FR α protein expression in ACC of the head and neck. Furthermore, the association with clinicopathologic parameters and outcome was investigated.

Patients and Methods

Patients and Study Design

Forty-three patients with ACC of the head and neck were included in this retrospective study. They were treated at the Department of Otorhinolaryngology, Head and Neck Surgery of the Medical University of Vienna between 1996 and 2016. Exclusion criteria were diagnosis of a second carcinoma, age under 18 years or incomplete patient records. Data were obtained by review of medical patient records. The study was approved by the institution's ethics committee (EK 1517/2018) and complies with the Declaration of Helsinki. All patients who are treated at the Department of Otorhinolaryngology of Medical University of Vienna comply with scientific use of their data. Therefore, no additional written consent had to be obtained for this retrospective study.

Patient and Public Involvement

It was not appropriate or possible to involve patients or the public in the design, or conduct, or reporting or dissemination plans of our research.

Tissue Microarray and Immunohistochemistry

A tissue microarray with three tumor cores and two tumor-free margin cores per patient was analyzed for FR α expression using immunohistochemistry. In short, the tissue was deparaffinized and rehydrated. FR α was stained using the Folate Receptor alpha IHC Assay Kit (Biocare Medical, CA, USA). The staining was visualized using AEC Substrate Kit (BD Biosciences, NJ, USA) and counterstaining was performed with Mayer's hemalum solution. Tissue slides were scanned using PANNORAMIC Digital Slide Scanner. Analysis of staining intensity was performed using QuPath (Version 0.2.3) under the visual control of the researcher J.S. Tissue was analyzed for the intensity of staining (negative, low positive, moderately positive, high positive) and the percentage (0–100%) of stained cells. To stratify protein levels, a score was calculated (3 x % of cells with high positive staining + 2 x % of cells with moderately positive staining + 1 x % of cells with low positive staining) ranging from 0 to 300. Protein expression was considered positive when the calculated score was >5, indicating positive staining at any intensity in more than 5% of cells. Positive protein levels were further stratified into low positive (5–15), moderately positive (15–50) and high positive (>50).

Statistical Analysis

Statistical analysis was calculated with Stata (Stata Corp., TX, USA) and visualized using Prism GraphPad software (GraphPad Software, CA, USA). FR α was correlated with clinicopathological parameters (sex, age, staging, grading, perineural invasion, lymphovascular invasion) using Fisher's exact or chi-squared test. The median survival was calculated using the method by Schemper et al.¹⁹ Overall survival (OS), cause-specific survival (CSS) or disease-free survival (DFS) were calculated from the date of surgery to the date of death, disease-specific death or recurrence, respectively. Survival curves were visualized using Kaplan–Meier curves and analyzed for significance using Log rank test. The cox proportional hazard model was used to calculate uni- and multivariable analysis. The multivariable model was corrected for staging and perineural invasion. Continuous data are reported as median and 25th and 75th percentiles and categorical values as absolute frequencies.

Results

Baseline Analysis

Forty-three patients with ACC of the head and neck were included in this study (Table 1). Fifty-three percent (n = 23) of patients were female. Most patients presented with an advanced stage (II–IV in 72%, n = 31) without lymph node metastasis (N0 in 77%, n = 33) or distant metastasis (M0 in 93%, n = 40). Perineural invasion was present in 51% (n = 22). Patients were treated with primary resection in 88% (n = 36) and postoperative radiotherapy in 46% (n = 19) and/or chemotherapy in 20% (n = 8). The median observation period was 77 months (49–173). The median OS was 121 months (76–173), the median CSS was 121 months (49–not reached) and the median DFS was 52 months (25–not reached). Fifty-two percent (n = 22) of patients developed a recurrence.

Expression of FR α and Correlation with Clinicopathological Features

FR α expression was investigated using immunohistochemistry and was considered positive if more than 5% of cells expressed FR α . ACC FR α staining was positive in 47% (n = 20) and was generally localized in the membrane and the cytoplasm (Figure 1). In detail, FR α staining was low positive in 21% (n = 9), moderately positive in 19% (n = 8) and high positive in 5% (n = 2). The median FR α expression score was 2.6 (0.1–17.7). All FR α positive tissues showed cytoplasmic staining of granules. Tumor-free margin tissue was available in 74% (n = 32) and was FR α -positive in 22%

Table 1 Baseline patient characteristics of adenoid cystic carcinoma patients

		Number of Patients	Percentage (%)
Sex	Female	23	53%
	Male	20	47%
T Stage	I	5	12%
	2	6	14%
	3	8	19%
	4	23	53%
	x	1	2%
	N Stage	0	33
	1	4	9%
	2	6	14%
M Stage	0	40	93%
	1	3	7%
Stage	I	5	12%
	II	7	16%
	III	5	12%
	IV	25	58%
	x	1	2%
Grading - Spiro	1	26	60%
	2	10	23%
	3	3	7%
	x	4	9%
Grading - Perzin/Szanto	1	7	16%
	2	22	51%
	3	10	23%
	x	4	9%
Localization	Minor	28	65%
	Major	15	35%
Perineural Invasion	No	21	49%
	Yes	22	51%
Lymphovascular Invasion	No	37	86%
	Yes	6	14%

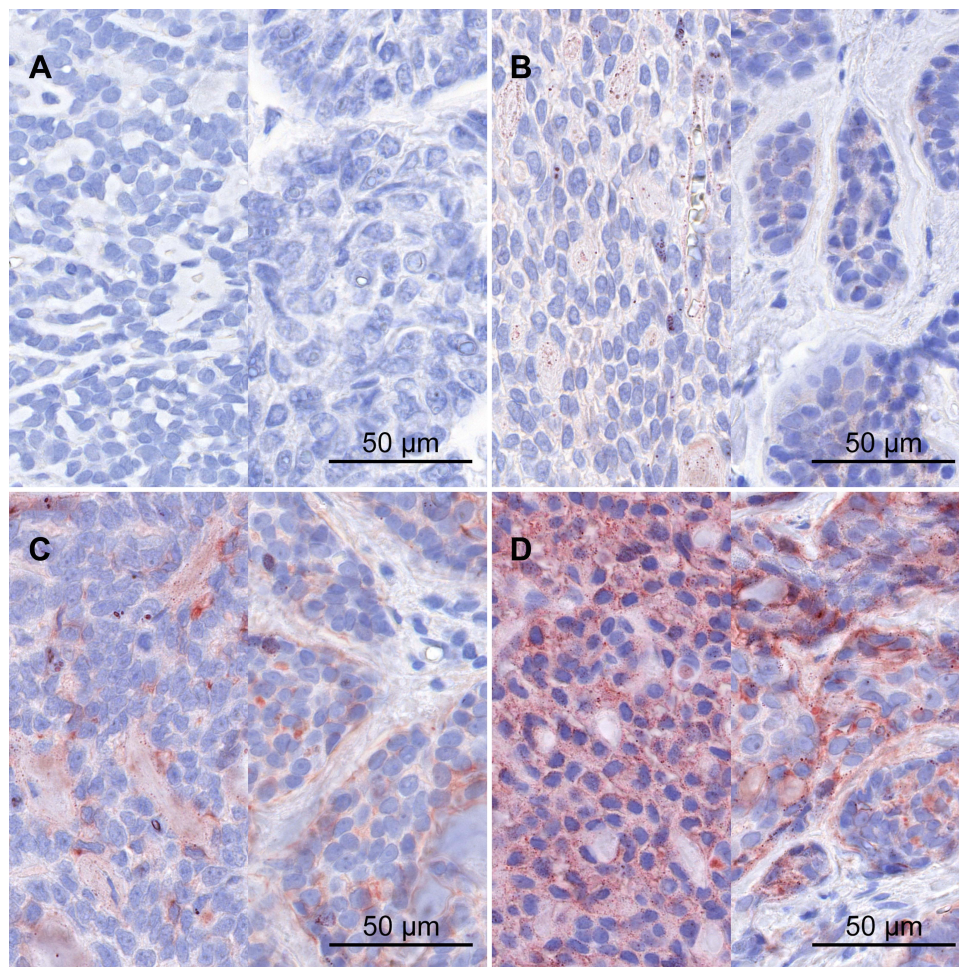


Figure 1 (A) Negative, (B) low positive, (C) moderately positive and (D) high positive staining of FR α in ACC.

($n = 7$) of patients. The median FR α expression score in the tumor-free margin was 0.8 (0.2–4.7). In detail, margin tissue was low positive in 13% ($n = 4$), moderately positive in 6% ($n = 2$) and high positive in 3% ($n = 1$). 55% ($n = 6$) of patients with positive tumor staining showed positive margin staining (fisher's exact $p = 0.003$). Association with clinicopathological parameters (sex, age, staging, grading, perineural invasion, lymphovascular invasion) was investigated using Fisher's exact and chi-squared test (Table 2). However, no association was found.

Analysis of Cause-Specific Survival and Disease-Free Survival

The association of FR α expression was investigated for the association with CSS and DFS (Figure 2). Patients with positive FR α levels showed a longer CSS (121 months vs not reached, $p = 0.093$) and DFS (48 vs 51 months, $p = 0.826$); however, the difference was not significant. Next, uni- and multivariable analysis, corrected for staging and perineural invasion, was performed. There was no significant change in risk for death or disease recurrence (all $p > 0.05$, Table 3).

Discussion

ACC of the head and neck is one of the most common salivary gland malignancies. Long-term survival rates decrease steadily over time since the disease is characterized by late recurrences and distant metastasis. The preferred therapeutic options are surgery and radiotherapy. Due to the slow-growing characteristics of the disease the effect of chemotherapy is dismal. Therefore, investigation of new therapeutic options and biomarkers is required.^{3,4}

In this study, FR α protein expression was evaluated in 43 patients with ACC of the head and neck using immunohistochemistry. FR α levels were positive in 47% of patients with ACC of the head and neck. The intensity of

Table 2 Correlation analysis for associations between expression of FR α and clinicopathological features

		FR α		
		Negative	Positive	p value
Sex	Female	12 (52%)	11 (55%)	0.853
	Male	11 (48%)	9 (45%)	
Age	≤59	10 (43%)	9 (45%)	0.92
	>59	13 (57%)	11 (55%)	
T Stage	T1-2	5 (22%)	6 (32%)	0.504
	T3-4	18 (78%)	13 (68%)	
N Stage	N0	16 (70%)	17 (85%)	0.294
	N1-2	7 (30%)	3 (15%)	
M Stage	M0	20 (87%)	20 (100%)	0.236
	M1	3 (13%)	0 (0%)	
Stage	I-II	5 (22%)	7 (37%)	0.323
	III-IV	18 (78%)	12 (63%)	
	Grading - Spiro	1	12 (57%)	
	2	7 (33%)	3 (17%)	
	3	2 (%)	1 (%)	
Grading - Perzin/Szanto	1	3 (14%)	4 (22%)	0.56
	2	11 (52%)	11 (61%)	
	3	7 (33%)	3 (17%)	
Localization	Minor	16 (70%)	12 (60%)	0.512
	Major	7 (30%)	8 (40%)	
Perineural invasion	No	12 (52%)	9 (45%)	0.639
	Yes	11 (48%)	11 (55%)	
Lymphovascular Invasion	No	19 (83%)	18 (90%)	0.669
	Yes	4 (17%)	2 (10%)	

Note: Correlation was analyzed using Fisher's exact or chi-squared test.

staining intensity was mostly low (21%) and moderate (19%), and only 5% showed high FR α staining. The staining was generally localized in the cytoplasm and membrane, with stained granules in all positive cells. This staining pattern is consistent with the transport mechanism of FR α . Folate is bound by membranous FR α . Subsequently, the folate-bound receptor is invaginated and transported into the cytoplasm as an endosome. Here, the pH in the endosomes acidifies and causes the release of folate from FR α , which further allows the transport of folate into the cytoplasm.²⁰ Therefore, we hypothesize that the granules found in the immunohistochemical staining may represent the formed endosomes with

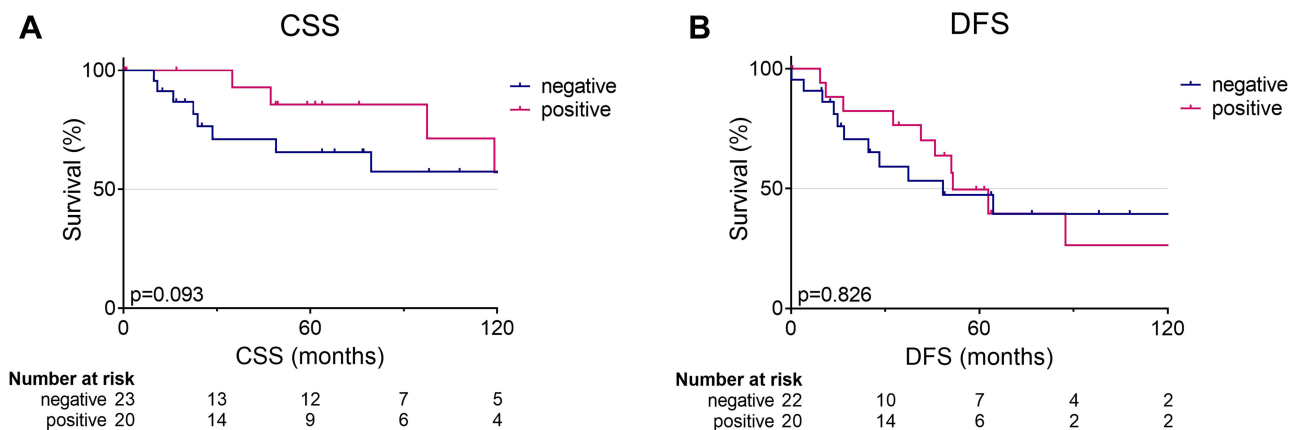


Figure 2 Kaplan–Meier survival curves for **(A)** cause-specific survival (CSS) and **(B)** disease-free survival (DFS) and FR α protein expression. Survival was analyzed using log-rank test. p, log-rank p value.

Table 3 Univariable and multivariable analysis of cause-specific survival (CSS) and disease-free survival (DFS) and FR α expression

		Univariable			Multivariable		
		HR	95% CI	p value	HR	95% CI	p value
CSS	FR α	0.39	0.12–1.22	0.105	0.48	0.14–1.67	0.247
	FR α score	0.66	0.34–1.28	0.221	0.68	0.35–1.31	0.249
DFS	FR α	0.91	0.38–2.15	0.826	1.04	0.41–2.63	0.932
	FR α score	1.23	0.81–1.88	0.332	1.83	0.80–2.03	0.305

Note: Multivariable analysis was corrected for staging and perineural invasion.

Abbreviations: HR, hazard ratio; 95% CI, 95% confidence interval.

folate-bound FR α . In conjunction with the membranous FR α staining, this indicates active FR α folate transport in ACC. However, the granules were not analyzed for endosomal markers.

Different therapeutic approaches targeting FR α , such as small molecules, antibodies and drug conjugates, are currently under investigation.⁵ The observed FR α staining in ACC of the head and neck indicates a mostly weak to moderate heterogeneous staining pattern. Patient outcome was not associated with FR α levels. In ovarian cancer and lung adenocarcinoma, FR α expression is mostly moderate or strong.^{8,10} While FR α is linked to a worse prognosis in ovarian cancer, high expression of FR α was associated with a better prognosis in lung cancer.^{11,21} In ovarian cancer, patients who received additional Vintafolide, a folate-conjugate, showed a better progression-free survival. When analyzed for FR α expression with Etarfolatide (a folate-technetium conjugate imaging agent), patients with 100% FR α expression showed the highest benefit.²¹ In contrast, there are also treatment options which may tolerate heterogeneous FR α expression. For example, Mirvetuximab, an antibody–drug conjugate, showed a cytotoxic effect in FR α -negative cells adjacent to FR α -positive cells.²² However, in a Phase III trial, ovarian cancer patients with high levels of FR α showed a better response regarding secondary endpoints but no difference in progression-free survival.¹⁸

Next, the tumor-free margin was analyzed. Here, the tumor-free margin tissue showed (mostly low) positive FR α staining in 22%. Interestingly, patients with positive FR α levels in the tumor showed positive margin staining in 55%. However, margin tissue was only available for 74% of ACC patients. In normal tissue FR α generally shows limited expression. Positive FR α expression is reported in the salivary glands, pancreas, thyroid, kidney, lung, placenta and breast.^{11,23} In contrast to our results, O'Shannessy et al observed strong staining of all investigated salivary gland samples (n = 3).¹¹ When the radiolabeled folate [¹⁸F]AzaFol was investigated as a PET radiotracer for FR α -imaging, the uptake in salivary glands was generally low.²⁴ Due to the limited expression of FR α in normal tissue which is mainly present at the apical surface, adverse effects of FR α targeted therapies may be less than those of chemotherapy.^{7,18} However, based on the available data, no clear conclusion can be drawn regarding the physiological expression of FR α in salivary glands.

Limitations, of this study are the retrospective setting and the small study cohort. FR α staining was investigated on a tissue microarray with three representative cores per tumor and two cores per tumor-free margin. However, distribution of staining may vary when examined on whole tissue slides. Therefore, external validation on whole tissue slides or using FR α specific imaging is recommended to further evaluate the feasibility of FR α targeted therapy in ACC of the head and neck. Furthermore, the margin samples are microscopically tumor-free, but may be altered at the molecular level.

In conclusion, FR α protein is present in 47% of ACC of the head and neck and shows no association with patient outcome. Based on the observed staining pattern which indicates active FR α transport mechanism, further evaluation of FR α as a targeted therapy in ACC of the head and neck is warranted. Altogether, a more detailed analysis is needed to further evaluate the distribution of FR α expression in ACC using either FR α specific imaging or whole tumor analysis.

Abbreviations

ACC, adenoid cystic carcinoma; CSS, cause-specific survival; DFS, disease-free survival; FR α , folate receptor alpha; OS, overall survival; PCFT, proton-coupled folate transporter; RFC, reduced folate carrier.

Data Sharing Statement

The datasets of this study are available from the corresponding author on reasonable request.

Ethics Approval

This study was approved by the ethics committee of the Medical University of Vienna (EK 1517/2018).

Funding

There is no funding to report.

Disclosure

The authors declare that they have no conflicts of interest in this work.

References

1. Bradley PJ. Adenoid cystic carcinoma evaluation and management: progress with optimism! *Curr Opin Otolaryngol Head Neck Surg.* 2017;25(2):147–153. doi:10.1097/MOO.0000000000000347
2. Coca-Pelaz A, Rodrigo JP, Bradley PJ, et al. Adenoid cystic carcinoma of the head and neck - an update. *Oral Oncol.* 2015;51(7):652–661. doi:10.1016/j.oraloncology.2015.04.005
3. Lorini L, Ardighieri L, Bozzola A, et al. Prognosis and management of recurrent and/or metastatic head and neck adenoid cystic carcinoma. *Oral Oncol.* 2021;115:105213. doi:10.1016/j.oraloncology.2021.105213
4. Dillon PM, Chakraborty S, Moskaluk CA, Joshi PJ, Thomas CY. Adenoid cystic carcinoma: a review of recent advances, molecular targets, and clinical trials. *Head Neck.* 2016;38(4):620–627. doi:10.1002/hed.23925
5. Scaranti M, Cojocaru E, Banerjee S, Banerji U. Exploiting the folate receptor α in oncology. *Nat Rev Clin Oncol.* 2020;17(6):349–359. doi:10.1038/s41571-020-0339-5
6. Cheung A, Bax HJ, Josephs DH, et al. Targeting folate receptor alpha for cancer treatment. *Oncotarget.* 2016;7(32):52553–52574. doi:10.18632/oncotarget.9651
7. Birrer MJ, Betella I, Martin LP, Moore KN. Is targeting the folate receptor in ovarian cancer coming of age? *Oncologist.* 2019;24(4):425–429. doi:10.1634/theoncologist.2018-0459
8. Markert S, Lassmann S, Gabriel B, et al. Alpha-folate receptor expression in epithelial ovarian carcinoma and non-neoplastic ovarian tissue. *Anticancer Res.* 2008;28(6A):3567–3572.
9. Köbel M, Madore J, Ramus SJ, et al. Evidence for a time-dependent association between FOLR1 expression and survival from ovarian carcinoma: implications for clinical testing. An ovarian tumour tissue analysis consortium study. *Br J Cancer.* 2014;111(12):2297–2307. doi:10.1038/bjc.2014.567
10. Kalli KR, Oberg AL, Keeney GL, et al. Folate receptor alpha as a tumor target in epithelial ovarian cancer. *Gynecol Oncol.* 2008;108(3):619–626. doi:10.1016/j.ygyno.2007.11.020
11. O'Shannessy DJ, Yu G, Smale R, et al. Folate receptor alpha expression in lung cancer: diagnostic and prognostic significance. *Oncotarget.* 2012;3(4):414–425. doi:10.18632/oncotarget.519
12. Bremer RE, Scoggin TS, Somers EB, O'Shannessy DJ, Tacha DE. Interobserver agreement and assay reproducibility of folate receptor α expression in lung adenocarcinoma: a prognostic marker and potential therapeutic target. *Arch Pathol Lab Med.* 2013;137(12):1747–1752. doi:10.5858/arpa.2013-0039-OA
13. Zagorac I, Lončar B, Dmitrović B, Kralik K, Kovačević A. Correlation of folate receptor alpha expression with clinicopathological parameters and outcome in triple negative breast cancer. *Ann Diagn Pathol.* 2020;48:151596. doi:10.1016/j.anndiagpath.2020.151596
14. ClinicalTrials.gov. Available from: https://clinicaltrials.gov/ct2/results?term=folate+receptor+alpha&Search=Apply&age_v=&gndr=&type=Intr&rslt=. Accessed May 10, 2022.
15. O'Malley DM, Matulonis UA, Birrer MJ, et al. Phase Ib study of mirvetuximab soravtansine, a folate receptor alpha (FR α)-targeting antibody-drug conjugate (ADC), in combination with bevacizumab in patients with platinum-resistant ovarian cancer. *Gynecol Oncol.* 2020;157(2):379–385. doi:10.1016/j.ygyno.2020.01.037
16. Shimizu T, Fujiwara Y, Yonemori K, et al. First-in-human Phase 1 study of MORAb-202, an antibody-Drug conjugate comprising farletuzumab linked to Eribulin Mesylate, in patients with folate receptor- α -Positive advanced solid tumors. *Clin Cancer Res.* 2021;27(14):3905–3915. doi:10.1158/1078-0432.CCR-20-4740
17. Moore KN, Vergote I, Oaknin A, et al. FORWARD I: a Phase III study of mirvetuximab soravtansine versus chemotherapy in platinum-resistant ovarian cancer. *Futur Oncol.* 2018;14(17):1669–1678. doi:10.2217/fo-2017-0646
18. Moore KN, Oza AM, Colombo N, et al. Phase III, randomized trial of mirvetuximab soravtansine versus chemotherapy in patients with platinum-resistant ovarian cancer: primary analysis of FORWARD I. *Ann Oncol.* 2021;32(6):757–765. doi:10.1016/j.annonc.2021.02.017
19. Schemper M, Smith TL. A note on quantifying follow-up in studies of failure time. *Control Clin Trials.* 1996;17(4):343–346. doi:10.1016/0197-2456(96)00075-X
20. Desai A, Sequeira JM, Quadros EV. The metabolic basis for developmental disorders due to defective folate transport. *Biochimie.* 2016;126:31–42. doi:10.1016/j.biochi.2016.02.012
21. Naumann RW, Coleman RL, Burger RA, et al. PRECEDENT: a randomized Phase II trial comparing vintafolide (EC145) and pegylated liposomal doxorubicin (PLD) in combination versus PLD alone in patients with platinum-resistant ovarian cancer. *J Clin Oncol.* 2013;31(35):4400–4406. doi:10.1200/JCO.2013.49.7685

22. Ab O, Whiteman KR, Bartle LM, et al. IMGN853, a folate receptor- α (FR α)-targeting antibody-drug conjugate, exhibits potent targeted antitumor activity against FR α -expressing tumors. *Mol Cancer Ther.* 2015;14(7):1605–1613. doi:10.1158/1535-7163.MCT-14-1095
23. Weitman SD, Lark RH, Coney LR, et al. Distribution of the folate receptor GP38 in normal and malignant cell lines and tissues. *Cancer Res.* 1992;52(12):3396–3401.
24. Gnesin S, Müller J, Burger IA, et al. Radiation dosimetry of 18F-AzaFol: a first in-human use of a folate receptor PET tracer. *EJNMMI Res.* 2020;10(1). doi:10.1186/s13550-020-00624-2

OncoTargets and Therapy

Dovepress

Publish your work in this journal

OncoTargets and Therapy is an international, peer-reviewed, open access journal focusing on the pathological basis of all cancers, potential targets for therapy and treatment protocols employed to improve the management of cancer patients. The journal also focuses on the impact of management programs and new therapeutic agents and protocols on patient perspectives such as quality of life, adherence and satisfaction. The manuscript management system is completely online and includes a very quick and fair peer-review system, which is all easy to use. Visit <http://www.dovepress.com/testimonials.php> to read real quotes from published authors.

Submit your manuscript here: <https://www.dovepress.com/oncotargets-and-therapy-journal>