

Aus dem Department für Kleintiere und Pferde der Veterinärmedizinischen Universität Wien

(Departmentsprecher: O.Univ.-Prof. Dr. med. vet. Joerg Aurich)

Universitätsklinik für Kleintiere

Klinische Abteilung für Interne Medizin Kleintiere

**A novel video-endoscope-guided myringotomy technique in dogs: Investigation in the value of vertical access to the tympanic membrane from beneath the patient**



**INAUGURAL-DISSERTATION**

zur Erlangung der Würde eines

**DOCTOR MEDICINAE VETERINARIAE**

der Veterinärmedizinischen Universität Wien

vorgelegt von

Mag. Amirhossein Mohammaddavoodi

Wien, im Juli 2021

**Betreuer**

Ao. Univ. Prof. Dr. med. vet. Reinhard Hirt Dipl. ECVIM-CA  
Department für Kleintiere und Pferde,  
Institut/Klinik für Interne Medizin Kleintiere  
Veterinärmedizinische Universität Wien  
Veterinärplatz 1  
1210 Wien

**Gutachterin**

Priv. Doz. Dr. habil. Barbara Bockstahler, Diplomate ECVSMR, ACVSMR, FTA, CCRP  
Department für Kleintiere und Pferde, Klinik für Kleintierchirurgie  
Ambulanz für Physikalische Medizin und Rehabilitation  
Veterinärmedizinische Universität Wien  
Veterinärplatz 1  
1210 Wien

## **Danksagung**

An dieser Stelle möchte ich mich von ganzem Herzen bei meiner großartigen Betreuerin Frau MVDr. Lucia Panakova Dipl. ECVD bedanken. Sie hat mich mit viel Geduld durch diese Arbeit geführt und war zu jeder Zeit bei der Lösung vieler kleiner und auch größerer Probleme stets behilflich.

Großer Dank gebührt auch meinem Betreuer, Prof. Reinhard Hirt, der stets da war, um mit seiner wissenschaftlichen Expertise das Projekt und die Publikation in die richtige Form zu bringen.

Ein besonderer Dank gilt Frau Prof. Dr. Sibylle Kneissl und den MitarbeiterInnen der Bildgebenden Diagnostik für die Hilfestellungen bei dieser Arbeit.

Wien, im Juli 2021

Amirhossein Mohammaddavoodi

## Table of Contents

<b>1</b>	<b>INTRODUCTION.....</b>	<b>1</b>
1.1	AIMS OF THE STUDY.....	2
1.2	HYPOTHESIS .....	2
<b>2</b>	<b>PUBLICATION .....</b>	<b>3</b>
<b>3</b>	<b>AWARD .....</b>	<b>9</b>
<b>4</b>	<b>SUMMARY .....</b>	<b>10</b>
4.1	SUMMARY .....	10
4.2	ZUSAMMENFASSUNG .....	11
4.3	ABBREVIATIONS .....	13
<b>5</b>	<b>BIBLIOGRAPHY .....</b>	<b>14</b>

## 1 Introduction

Otitis externa (OE) is a common disease (7.5 - 16.5%) in small animal practice (Fraser et al., 1969). A classification system called PSPP (primary causes, Secondary causes, Perpetuating factors and Predisposing factors) was designed to assist in the logical approach necessary for the successful treatment of chronic otitis externa in dogs (Griffin, 2010). According to this classification system allergies, foreign bodies, parasites, endocrine disorders, immune mediate diseases and keratinisation disorders are so called primary causes of OE. Bacterial and yeast infections, as well as local drug reactions belong to the secondary causes of OE. Perpetuating factors cause changes in morphology and disruption of physiology of the ear canal as well as the middle ear. Examples are changes caused by perforated tympanic membrane (TM) and otitis media (OM), hyperplastic, proliferative, stenotic or calcified ear canals, neoplasia and polyp. Predisposing factors are pendulous pinna, narrow ear canals, excessive moisture, excessive hair growth in the ear canal and trauma from cleaning of the ear canal. According to Cole et al. (1998), a high percentage (82%) of dogs with chronic OE may develop concurrent OM, with the majority (71%) of reported cases having an intact tympanic membrane (TM) (Cole et al., 1998). Chronic cases of OE can extend into the middle ear cavity and thus cause otitis media (OM) (Fraser et al., 1969). Unrecognized OM is also a reason for unsuccessful treatment of OE (Lane & Little 1986). Therefore, OM should be always ruled out in chronic or recurrent OE (Rose 1977, Logas 1994, Cole et al. 2002). In addition, primary secretory otitis media (PSOM) or middle ear effusion (MEE), reported in over 60% in Cavalier Kings Charles Spaniel (CKCS), can occasionally lead to OE (Owen et al. 2004, Stern-Sertholtz et al. 2003).

Different diagnostic procedures for OM are available in veterinary medicine. Cytological examination and microbial culture of middle ear cavity (MEC) contents sampled via myringotomy (Cole et al., 1998; Griffin, 2006; Shell, 1988), as well as video-otoscopy (VO), computed tomography (CT) and magnetic resonance imaging (MRI) are currently applied to diagnose OM (Belmudes et al., 2018; Classen et al., 2016; Garosi et al., 2003). CT scans have become widely available and currently are considered the gold standard for diagnosis of middle ear problems (Classen et al. 2016).

Myringotomy is a minimally invasive method reaching the MEC, that will allow the access from the EEC through the TM intending pressure decrease of the middle ear, specimen collection for cytology and microbial cultures, and even possible drug application directly into the MEC (Rose

et al. 1977, Bruyette et al. 1993). Detection of any fluid within the MEC is suggestive either for infectious OM (Dickie, 2003), or a non-infectious OM, but can also be an accidental finding with the fluid filled non-inflammatory MEC. The middle ears contents in MEE in CKS are sterile, mucoid, thick grey-yellowish fluid and can be sampled via myringotomy (Cole et al. 2011). Flushing of the MEC after a myringotomy is a common therapeutic method for management of MME, although placement of a tympanostomy tube has been reported (Cole et al. 2011, Cole et al. 2012). Bacterial infections of the MEC tend to progress and may cause changes of the middle ear wall, or even otitis interna (OI). It is crucial to avoid the iatrogenic contamination of the MEC during material collection via myringotomy. In a previous study by Reinbacher et al. (2020) on canine otitis-free cadavers, specimens from the MEC obtained via video-otoscopically controlled myringotomy were contaminated with the EEC content in over 67% of cases. In this study, contamination of MEC aspirates was confirmed by the presence of fluorescent dye introduced into the EEC before aspiration. The effects of gravity were probably the main cause for the high contamination rate of MEC aspirates obtained via myringotomy.

### **1.1 Aims of the study**

1. To investigate the influence of gravity on contamination rate of MEC aspirates via myringotomy
2. To design and evaluate a novel myringotomy method in order to avoid contamination MEC from external ear canal

### **1.2 Hypothesis**

We hypothesized that there would be less or even no contamination of middle ear aspirates from the external ear canal while performing myringotomy from beneath the dogs without interference of gravity in this study.



## Original Article

# A novel video-endoscope-guided myringotomy technique in dogs: Investigation in the value of vertical access to the tympanic membrane from beneath the patient - a pilot study

A. Mohammaddavoodi<sup>a,\*</sup>, S. Kneissl<sup>b</sup>, R. Hirt<sup>a</sup>, J. Spargser<sup>c</sup>, M. Aghapour<sup>d</sup>, L. Panakova<sup>a</sup><sup>a</sup> Clinical Unit of Internal Medicine Small Animals, Department for Companion Animals and Horses, Vetmeduni Vienna, Veterinärplatz 1, 1210 Vienna, Austria<sup>b</sup> Clinical Unit of Diagnostic Imaging, Department for Companion Animals and Horses, Vetmeduni Vienna, Veterinärplatz 1, 1210 Vienna, Austria<sup>c</sup> Institute of Microbiology, Department of Pathobiology, Vetmeduni Vienna, Veterinärplatz 1, 1210 Vienna, Austria<sup>d</sup> Clinical unit of Small Animal Surgery, Department for Companion Animals and Horses, Vetmeduni Vienna, Veterinärplatz 1, 1210 Vienna, Austria

## ARTICLE INFO

## Keywords:

Dogs  
External ear canal  
Otitis externa  
Tympanic membrane  
Middle ear cavity  
Otitis media  
Myringotomy

## ABSTRACT

Myringotomy is a well-accepted method for diagnosing and treating otitis media in dogs having an intact tympanic membrane. In a recent study, the contamination rate of middle ear aspirates from the external ear canal via myringotomy was 67%. To evaluate the iatrogenic contamination rate of the middle ear aspirates by material from the ear canal, using a novel technique: Vertical access to the tympanic membrane from beneath the patient. Thirty-six ears from 20 canine Fresh cadavers with a CT scan negative for otitis externa and otitis media were video-otoscopically flushed with the ear upside. The instillation of the fluorescent dye into the ear canal and immediate retrieval were performed. With the patient positioned on a custom-made fenestrated table plate, a modified video-otoscopically guided myringotomy approaching the tympanum vertically from underneath, was performed. Contamination rates were assessed by the visual detection of fluorescent dye within the aspirated fluid, either by yellow staining solely, or a positive fluorescence test. Cytology and microbial cultivation were accomplished.

Middle ear sample contamination by the material from the ear canal was identified in 2 of 36 (5.55%) ears. Neither a change in colour nor fluorescence was detected in 34 of 36 (94.44%) middle ear samples. Sixteen of 36 (44.44%) external ear canal samples and 4 of 36 (11.11%) middle ear aspirates had positive bacterial culture. This novel technique is a promising method for middle ear material collection in patients with concurrent otitis externa.

## 1. Introduction

Otitis externa (OE) is one of the most common diseases (7.5 - 16.5%) in small animal practice (Fraser, Gregor, Mackenzie, Spreull & Withers, 1969). In chronic cases, it can extend to otitis media (OM) (Fraser et al., 1969). According to Cole, Kwochka, Kowalski and Hillier (1998), a high percentage (82%) of dogs with chronic OE may develop concurrent OM, with the majority (71%) of reported cases having an intact tympanic membrane (TM) (Cole et al., 1998). Diagnosis of OM can be challenging, and a variety of diagnostic procedures has been reported. Cytological examination and microbial culture of middle ear cavity (MEC) contents sampled via myringotomy (Cole et al., 1998; Griffin, 2006; Shell, 1988). video-otoscopy (VO) and computed tomography (CT) or magnetic resonance imaging (MRI) are currently applied to diagnose OM

(Belmudes et al., 2018; Classen, Bruehschwein, Meyer-Lindenberg & Mueller, 2016; Garosi, Dennis & Schwarz, 2003). For detection of middle ear disease, such procedures as radiography, ultrasound of MEC, tympanometry with handheld tympanometers, otoscopy and palpation of TM with a blunt probe, as well as virtual otoscopy were evaluated in canine ears (Classen et al., 2016; Hol, Walker, 1997; Little, Lane, 1989; Strain, Fernandes, 2015). CT scans have become widely available and currently are considered the gold standard for diagnosis of middle ear problems (Classen et al., 2016). Nevertheless, although as little as 0.1 mL of saline could be detected within the MEC on CT scans according to a pilot study (Cole, Samii, Wagner & Rajala-Schultz, 2015), this technique may occasionally overlook debris within the MEC (Cole et al., 2015).

Co-existing OM is an important cause for unsuccessful treatment of

\* Corresponding author: Amirhossein Mohammaddavoodi, Anton-Bosch-Gasse 25/1/3. 1210 Vienna, Austria,  
E-mail address: [Amirhosseind1981@gmail.com](mailto:Amirhosseind1981@gmail.com) (A. Mohammaddavoodi).

<https://doi.org/10.1016/j.vas.2021.100173>

Received 17 October 2020; Accepted 11 March 2021

Available online 13 March 2021

2451-943X/© 2021 The Authors.

Published by Elsevier Ltd.

This is an open access article under the CC BY-NC-ND license

<http://creativecommons.org/licenses/by-nc-nd/4.0/>.

OE (Lane, Little, 1986). OM is a well-recognized perpetuating factor of chronic OE<sup>14</sup> and if unrecognized or untreated will often cause recurrent OE (Griffin, 2010; Paterson, 2016). Thus, OM should always be excluded in chronic or recurrent OE (Cole, Kwochka, Podell, Hillier & Smeak, 2002; Logas, 1994; Rose, 1977). Detection of fluid within the MEC is suggestive either for infectious OM (Dickie et al., 2003), or for a non-infected fluid filled MEC. Bacterial infections of the MEC tend to progress and may cause changes of the middle ear wall, or even otitis interna (OI). In addition to the aforementioned conditions, primary middle ear diseases have been described less frequently as OM with effusion in boxers and primary secretory otitis media (PSOM) in Cavalier King Charles Spaniels (CKCS) (Cole et al., 2015; Miller, Griffin & Campbell, 2013; Paterson, 2018). Therefore, material collection from the MEC and further analysis are necessary to differentiate between inflammatory infectious and non-infectious causes.

Myringotomy is a minimally invasive method providing access to the MEC for different purposes (Rose, 1977). It may lead to pressure reduction of the MEC, specimen collection for cytology and microbial cultures, and administration of drugs into the MEC (Bruyette & Lorenz, 1993; Rose, 1977). In a previous study by Reinbacher, Kneissl, Hirt, Spengler and Panakova (2020) on canine cadavers free from otitis, specimens from the MEC sampled via video-otoscopically controlled myringotomy were contaminated with material from EEC in over 67% of cases. In this study, contamination of MEC aspirates was confirmed by the presence of fluorescent dye introduced into the EEC before aspiration. Their hypothesis was, that during the myringotomy the gravity might help to transfer the EEC content into the MEC. The authors

assumed, that the effect of gravity was the main cause for the high contamination rate in the samples obtained via myringotomy.<sup>23</sup> In this way, the erroneous diagnosis of bacterial OM would possibly influence therapeutic decision making. Furthermore, contamination of a previously sterile MEC could potentially harm the patient and should be avoided. Therefore, a new sampling method allowing for the retrieval of MEC material with a minimized contamination risk is necessary. Our hypothesis was, that the novel modified myringotomy technique would prevent contamination of MEC aspirates from the EEC. With the patient in lateral recumbency on the working table and the examiner underneath the patient, approaching the examined EEC vertically through the opening of this table plate, the effects of gravity would rather support spontaneous clearance of the EEC from the fluid remnants from the previous flushing.

## 2. Methods and materials

### 2.1. Inclusion criteria

The cadavers of 20 dogs of different breeds, sex and age euthanized for medical reasons unrelated to the present study were included (Table 1). To prevent influences of post mortem changes, all procedures were performed within 4 h after euthanasia. In cases of unilateral ear disease detected by the criteria described below, only the ear without any macroscopic signs of disease was included and further evaluated.

**Table 1**  
Details of results of myringotomy in vertical access to tympanic membrane in 36 ears.

Cadavers	Presence of the fluorescence in the specimen (yellow colour)	Microbial culture from the EEC	Microbial culture from the MEC
1 Golden Retriever	R*: NO L*: NO	R: <i>Bacillus licheniformis</i> L: <i>Streptococcus lutetiensis</i>	R: Negative L: Negative
2 Dogo Argentino	R: NO L: NO	R: Negative L: Negative	R: Negative L: Negative
3 Dachshund	R: YES L: NO	R: Negative L: <i>Klebsiella pneumoniae</i>	R: Negative L: Negative
4 Mix	L: NO	L: <i>Pseudomonas aeruginosa</i>	L: Negative
5 Chihuahua	R: NO L: NO	R: Negative L: <i>E. coli</i> , <i>Klebsiella oxytoca</i>	R: <i>E. coli</i> , <i>Klebsiella oxytoca</i> L: <i>E. coli</i> , <i>Klebsiella oxytoca</i> , <i>Staphylococcus pseudintermedius</i>
6 Bearded Collie	R: NO	R: <i>Staphylococcus pseudintermedius</i>	R: Negative
7 Dachshund	R: NO L: NO	R: <i>Staphylococcus pseudintermedius</i> L: Negative	R: Negative L: Negative
8 Small Münsterländer	R: NO L: NO	R: <i>Bacillus</i> spp. L: <i>Moraxella canis</i>	R: Negative L: Negative
9 Landseer	R: NO L: NO	R: Negative L: Negative	R: Negative L: Negative
10 Pekingese	R: NO L: NO	R: Negative L: <i>Streptococcus canis</i>	R: Negative L: <i>E. coli</i>
11 Eurasier	R: NO L: NO	R: Negative L: Negative	R: Negative L: Negative
12 Labrador Retriever	R: NO L: NO	R: <i>Staphylococcus hominis</i> L: <i>Staphylococcus hominis</i>	R: Negative L: Negative
13 Mix	L: NO	L: <i>Bacillus cereus</i>	L: <i>Bacillus cereus</i>
14 German Shepherd	R: NO	R: <i>Enterococcus mundtii</i> , <i>Streptococcus canis</i> L: <i>Bacillus mycoides</i>	R: Negative L: Negative
15 Pit Bull Terrier	R: NO L: NO	R: Negative L: Negative	R: Negative L: Negative
16 Mix	R: NO L: YES	R: Negative L: Negative	R: Negative L: Negative
17 Chihuahua	R: NO L: NO	R: Negative L: Negative	R: Negative L: Negative
18 Shetland Sheepdog	R: NO	R: Negative	R: Negative
19 Bernese Mountain Dog	R: NO L: NO	R: Negative L: Negative	R: Negative L: Negative
20 French Bulldog	R: NO L: NO	L: Negative L: <i>Acinetobacter radioresistens</i>	L: Negative L: Negative

\* R (Right), L (Left), EEC (external ear canal), MEC (middle ear cavity).



## 2.2. Exclusion criteria

Ears with signs of OE, perforated or non-visualized TM and ears, where CT scans demonstrated middle ear effusion, were excluded. Otoscopy with a handheld otoscope was used to rule out macroscopically inflamed ear canals. Furthermore, cytology samples from the EEC stained by a commercial Romanowsky stain (LT-SYS® Diff-Quick, labor + Technik Eberhard Lehmann GmbH; Berlin, Germany) were evaluated to detect inflammatory cells and bacteria or yeast, and to finally exclude ears with infection.

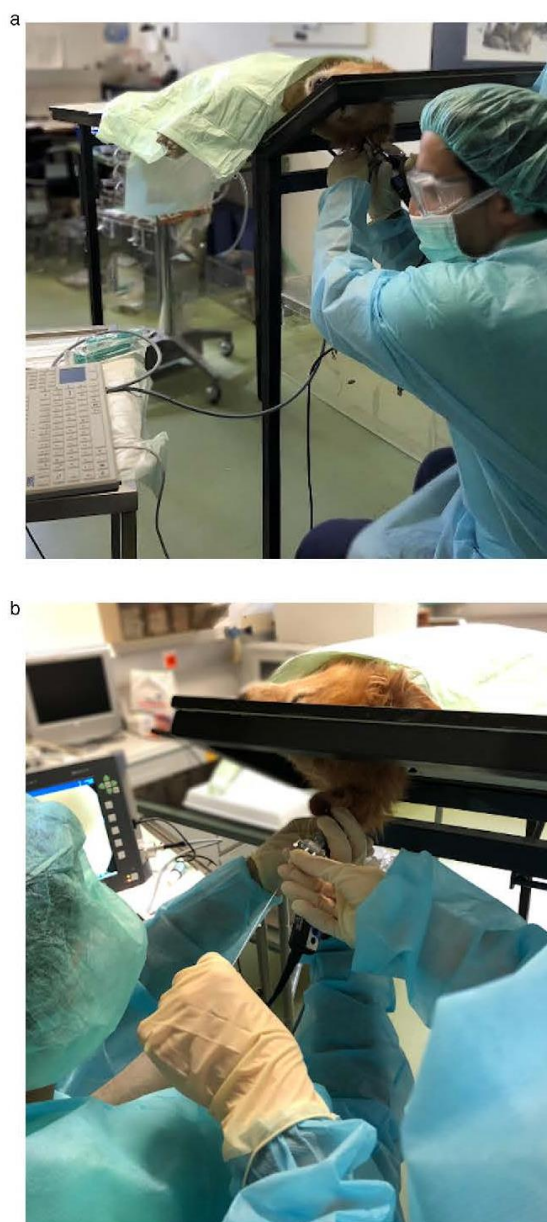
## 2.3. Custom-made myringotomy table

The custom-made wooden table plate was composed of two connected parts and positioned on two pairs of metal legs (120 cm height) connected with metal construction. The longer part of the plate (120×80 cm) was intended to accommodate the patient's body and was connected to the shorter part (25×80 cm) for the head at an angle of 30°. The shorter part had a rectangular otoscopy window (15×15 cm) located in the right corner of the table and was suited for the manipulation of the patient's head from below the patient (Fig. 1a, b).

## 2.4. Study protocol

Swabs for microbial cultivation and cytological assessment were obtained from the deep portion of all EECs initially, followed by otoscopic examination with a handheld otoscope in all cadavers. A CT scan of the MEC was performed to evaluate both middle ears. Cadavers were positioned in sternal recumbency with the head positioned on a radiolucent pillow. Images were acquired in soft tissue and bone algorithms, reconstructed utilizing multislice CT units (Emotion 16-slice configuration; Siemens AG Medical Solutions; Erlangen, Germany, kVp 120 to 140, mA 80 to 100, slice thickness and index 0.8 - 3 mm and 16 × 0.6 mm collimation, respectively).

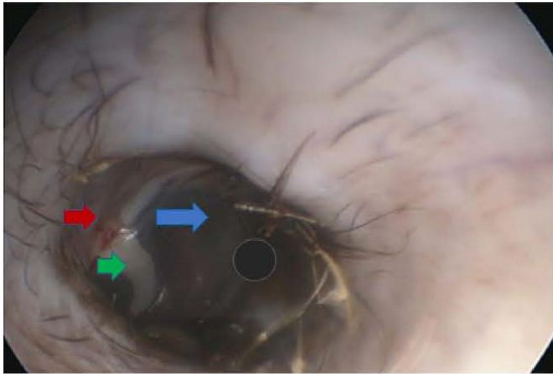
First, VO (Karl Storz GmbH & Co.KG, Berlin, Germany) was performed with the cadaver in lateral recumbency in a classical position; the ear under evaluation was directed upwards. The EEC was flushed with sterile 0.9% sodium chloride for at least 5 min, mimicking real conditions. If present, excessive amounts of hair or cerumen were removed from the EEC under video-otoscopic control to facilitate good access to the TM. After the TM was visualized, the residual flushing fluid was cautiously removed by gentle suction with a vacuum-pump (Vet-pump® 2 69,321,601: Karl Storz GmbH & Co.KG) attached to a soft feeding tube with the end cut 5 cm from the tip (Rüsch feeding tube Eruplast®, No.1, Rüsch Uruguay LTDA; Montevideo, Uruguay). Then, another tube was passed through the working canal of the video-otoscope, and intense yellow fluorescent dye (Fluorescein 1%, Lekareň Unimed Pharma; Bratislava, Slovakia) diluted with sterile 0.9% saline (1 drop fluorescent dye in 5 mL saline) was instilled into the deep portion of the EEC. The remaining yellow fluid was removed by vacuum-pump suction under the video-otoscopic control. Subsequently, the cadaver was placed on the custom-made myringotomy table, turned with the flushed ear directed downwards and with the head positioned over the "otoscopy window" (Fig. 1a). Next, myringotomy was performed after inserting the video-otoscope into the ear canal from underneath the table through the "otoscopy window". An assistant was manipulating the dog's head to optimize access to the TM. Once the video-otoscope was in the correct position and the TM was well visualized, a myringotomy needle of 1.5 mm diameter (myringotomy needle 67071XS, Karl Storz GmbH & Co. KG) was inserted through the working canal into the MEC (Fig. 1b), perforating the TM in the caudoventral aspect of the pars tensa (Fig. 2), thereby avoiding the "umbo". The needle stilet was removed and an empty sterile 2 mL syringe was attached to the conus of the myringotomy needle followed by an effort to aspirate the MEC content. If no fluid could be aspirated, another 2 mL syringe with sterile saline was attached to the myringotomy needle, 1 mL of saline was



**Fig. 1.** Performing myringotomy in vertical access to the tympanic membrane from beneath the patient on a cadaver positioned in lateral recumbency on custom-made myringotomy table with 120 cm height and an otoscopy window in 15 × 15 cm. (A) Positioning the video-otoscope without flushing in the ear canal to visualize tympanic membrane on the custom-made table. (B) Insertion of the myringotomy needle through ear canal and sampling from middle ear cavity.

administered directly into the MEC and re-aspirated. MEC aspirates were sampled for further analysis. Immediately after the procedure, the cadaver was turned back with the examined ear directed upwards, and the TM was inspected with the video-otoscope to confirm the presence of the just created TM perforation.





**Fig. 2.** External ear canal with intact semi-transparent tympanic membrane, pars flaccida (red arrowhead) on the dorsal part, the manubrium malleus (green arrowhead), pars tensa on the dorsal part (blue arrowhead) with an optimal and safe region for myringotomy in caudoventral quadrant (black dot).

## 2.5. Further laboratory analysis

### 2.5.1. Cytology

Cytology samples from the deep portion of each EEC were collected in the beginning of the procedure, immediately after sampling for microbiology, and prior to otoscopy with the handheld otoscope. Cytology samples were obtained via cotton swabs and rolled over the microscopy slide, air dried and stained with a Romanowsky type stain. One drop of the MEC aspirate was placed on a slide, air-dried, stained and examined microscopically for the presence of inflammatory cells, ciliated epithelia and microorganisms (rods, cocci, and yeast). Each slide was screened at low power (40x) magnification, and consecutively, 10 fields were scanned with high-power magnification (1000x) under oil-immersion. With this magnification, fields were screened and inflammatory cells, bacteria and yeast were counted. Detection of  $\geq 4$  mean bacteria and/or yeast counts per high power field, as well as the presence of inflammatory cells, were consistent with inflammation/infection of the EEC, resulting in rejection of the sample for further analysis (exclusion criteria).

### 2.5.2. Sample analysis

Visual analysis of the aspirated fluid specimen within the syringe with regard to colour (yellow or colourless) was performed by a person blinded to the dog's data. The same person evaluated for the presence of fluorescence of three sample drops applied on filter paper by use of a UV-light lamp (Atlas Fluotest, Karl Schreiner GmbH; Vienna, Austria). Positive fluorescence, as well as yellow staining of the fluid sample, indicated contamination of the MEC aspirate by material from the EEC.

### 2.5.3. Microbial culture

For microbial cultivation, swab (Transwab, medical Wire & Equipment Co; Corsham, UK) samples were obtained from the deep portion of each EEC. Microbial cultivation of the MEC content was performed on samples obtained by the new myringotomy technique described above. Swab samples and aspirates were streaked onto Columbia agar with 5% sheep blood (BBL™, BD Diagnostics, Heidelberg, Germany) and Chocolate II agar (BBL™, BD Diagnostics, Heidelberg, Germany) both incubated at 37 °C under microaerobic conditions, and onto Sabouraud Dextrose agar (BBL™, BD Diagnostics, Heidelberg, Germany) incubated in ambient air at 28 °C. Culture plates were daily examined for growth up to 7 days of incubation. Isolates were identified by matrix-assisted laser desorption/ionization-time of flight (MALDI-TOF) mass spectrometry (Bruker Daltonik GmbH, Bremen, German).

## 2.6. Statistical analysis

Statistical analysis was made on applying SPSS software (IBM Corp; USA) on the base of cross-tabulation. Associations between microbial cultures from EECs and MECs were calculated by Fisher's exact test. The significant rate of non-contaminated MEC aspirates was between 0% to 13%.

## 3. Results

From the 20 cadavers under investigation, 36 ears were included in this study. Four ears were excluded due to perforated TMs during performing VO and ear flush. CT scans from MECs were performed in all 20 cadavers, and none of the ears had signs of effusion within the MEC. In one cadaver (CAD 20), a 9-year-old French bulldog, thickening of the middle ear wall was detected on CT scans, which is a common finding in this breed, but no effusion was present. Therefore, this cadaver was also included.

The contamination rate of the MECs, as indicated by the presence of the fluorescent dye as well as microbial culture results of both EECs and MECs are shown in Table 1. In all 36 ears, no fluid, but only air was obtained with initial aspiration, and therefore, 1 mL sterile saline was administered into each middle ear through the myringotomy needle as described above, which was immediately retrieved. In only two of 36 (5.55%) samples from the MECs yellow staining, indicative of contamination, was detected (from the right ear in CAD 3 and from left ear in CAD 16). The remaining 34 samples (94.44%) were also negative for fluorescence by the UV-light on the filter paper.

In none of the samples from the EEC as well as the MEC inflammatory cells and rods were detected on cytological evaluation. The mean number of cocci and yeast in cytology from the EECs were less than 4 per high power field (1000x), further supporting the absence of OE. No bacteria and yeast were seen from MEC specimens.

Only 16 (44.44%) of 36 EEC samples had positive bacterial cultures and predominant bacteria were *Staphylococcus pseudintermedius*, *Staphylococcus hominis*, *Bacillus* spp., *Streptococcus* spp. and *Klebsiella* spp. Microbial cultures were positive only in four of 36 MEC samples (11.11%) (CAD 5 right ear: *E.coli*, *Klebsiella oxycota*, CAD 5 left ear: *E.coli*, *Klebsiella oxycota*, *Staphylococcus pseudintermedius*, CAD 10 left ear: *E.coli*, CAD 13 left ear: *Bacillus cereus*). No microorganisms were isolated from 32 of the 36 (88.89%) MEC specimens. In two of four cases, identical bacterial species (CAD 5 left ear: *E.coli*, *Klebsiella oxycota*, CAD 13 left ear: *Bacillus cereus*) were cultivated from both EECs and MECs; though, contamination was not demonstrated based on the colour/fluorescence of the MEC aspirates (Table 1 and 2). *Staphylococcus pseudintermedius* was also isolated from the MEC in CAD 5 (one ear), but not from the particular EEC. One cadaver (CAD 5 right ear) had a positive microbial culture from the middle ear (*E.coli*, *Klebsiella oxycota*), but a negative culture result from the EEC. The two dye-contaminated aspirates revealed negative microbial cultures in both EECs and MECs. Therefore, no association was seen between positive bacterial cultures and two contaminated aspirates (Table 2). The MEC aspirates were contaminated by the EEC in 5.55% (2/36), meaning this procedure provided non-contaminated material.

## 4. Discussion

Dogs with chronic or recurrent OE of more than 6 months duration may frequently develop concurrent OM (Cole et al., 1998, 2002; Rosychuk & Bloom 2010). Different authors have studied the importance of ruling out OM in patients with chronic OE even with intact TM. In an early study by Spruell, 52 from 100 cases with OE had OM with a perforated TM. However, myringotomy was not carried out in the remaining 48 ears with the intact TM (Spruell, 1964). More than 70% of OE cases with concurrent chronic OM were reported to have an intact TM in more recent studies (Cole et al., 1998, 2002). In contrast, in



**Table 2**

Association between contamination and microbial cultures from external ear canals (EECs) and middle ear cavities (MECs) in 36 ears.

		Negative bacterial culture MEC	Positive bacterial culture MEC
Not contaminated	Negative bacterial culture EEC	17	1
	Positive bacterial culture EEC	13	3
Contaminated	Negative bacterial culture EEC	2	0
	Positive bacterial culture EEC	0	0

Palmeiro's study, only 4.7% of 44 dogs with OM had an intact TM (Palmeiro, Morris, Wiemelt & Shofer, 2004). In a more recent study evaluating 214 ears of 122 dogs with chronic OE, 87 middle ears (40.7%) were found to have abnormalities on CT scans. Patients with proliferative OE had significantly more often changes indicative of OM (68%) in comparison to dogs with purulent OE (44.6%) (Belmudes et al., 2018).

Cytological evaluation of middle ear samples has been considered a crucial in the evaluation of the aspirate, while microbial culture was believed to be less reliable (Nuttall, 2016). It has been shown, that different bacteria may be isolated from two separate cultures from the same area of the EECs (Rosychuk & Bloom 2010; Schick, Angus & Coyner, 2007). In our study, though no microorganisms were detected on MEC cytology smears, it should be considered, that the retrieved material was already diluted with 1 mL saline, possibly leading to erroneously negative results. Centrifugation of the aspirate might be helpful, though the standard amount of 1 mL could not be collected from each MEC in our samples. Moreover, microbial cultures from the MECs were positive in only 4 out of 36 ears. In two of them, identical bacterial species were cultivated from corresponding EECs as well. There is a small chance that middle ear contamination occurred during the myringotomy procedure in these two samples, although the aspirated sample from the MEC did not match the criteria for contamination. In an early study on 30 dogs (60 ears) free from OE and OM identical bacterial species hardly ever were recovered in both EECs and MECs (Mastuda, Tojo, Fukui, Imori & Baba, 1984). In our study, only in one case different bacterial species were isolated from the MEC (CAD 10 left ear: *E. coli*) and corresponding EEC specimen (CAD 10 left EEC: *Streptococcus canis*). A positive microbial culture from the MEC aspirate (CAD 5 right ear: *E. coli*, *Klebsiella oxytoca*) and a negative from the corresponding EEC was seen only in one ear, but there was no history with regard to previous ear disease available for this dog. Since *Enterobacteriales* (e.g. *E. coli*, *Klebsiella* spp.) may also be present in the oropharynx and the upper respiratory tract (Daodu, Amosun & Oluwayelu, 2017), transition to MEC through the eustachian tube may also be another explanation of this positive culture of MEC.

Myringotomy is the best method to access the middle ear cavity in OM with an intact TM, or in the management of PSOM in CKCS (Bruyette & Lorenz, 1993; Owen, Lamb, Lu & Targett, 2004; Rose, 1977). The utter importance to avoid contamination of the MEC during myringotomy, especially when sampling through infected EECs, cannot be over-emphasized. Alternatively, specimens may be collected by more invasive surgical procedures such as ventral or lateral bulla osteotomy (Doyle, Skelly & Bellenger, 2004). Thus, these procedures are recommended only in end-stage middle ear disease or in conditions, which are not responsive to medical treatment (Krahwinkel, Pardo, Sims & Bubb, 1993).

The benefits of the new myringotomy technique described herein include prevention of sample contamination from the EEC and avoidance of the iatrogenic spread of infection from the EEC into the MEC. Performing this novel myringotomy technique may be physically challenging and training of this technique on cadavers prior to application on living patients seems to be mandatory. Furthermore, accomplishing this new technique in patients with stenotic or proliferative ear canals might prove more demanding or even impossible.

The high contamination rate (67%) of MEC samples with material from EEC reported in a previous study by Reinbacher et al. (2020) using

the traditional myringotomy technique might highlight the value of this novel technique in order to avoid MEC contamination.

## 5. Conclusions

This new method - vertical access to the tympanic membrane from beneath the patient - was successfully tested in cadavers with a very low contamination rate (5.55%). Based on our results, gravity is assumed to be the major reason transferring contamination from the EEC to the MEC during myringotomy. This new approach needs to be further evaluated in canine patients with chronic ear problems in future studies, in order to rule out middle ear disease in the initial phase of treatment. The markedly reduced contamination rate might further favour veterinarians to perform this method in cases where myringotomy is indicated.

## Declaration of Competing Interest

The authors declare that they have no known competing financial interests or personal relationships that could have appeared to influence the work reported in this paper.

## Acknowledgements

The authors would like to thank staff University hospital of Vetmeduni Vienna in particular the staff of Clinical Unit of Diagnostic Imaging of the University hospital of Vetmeduni Vienna for cooperation and support.

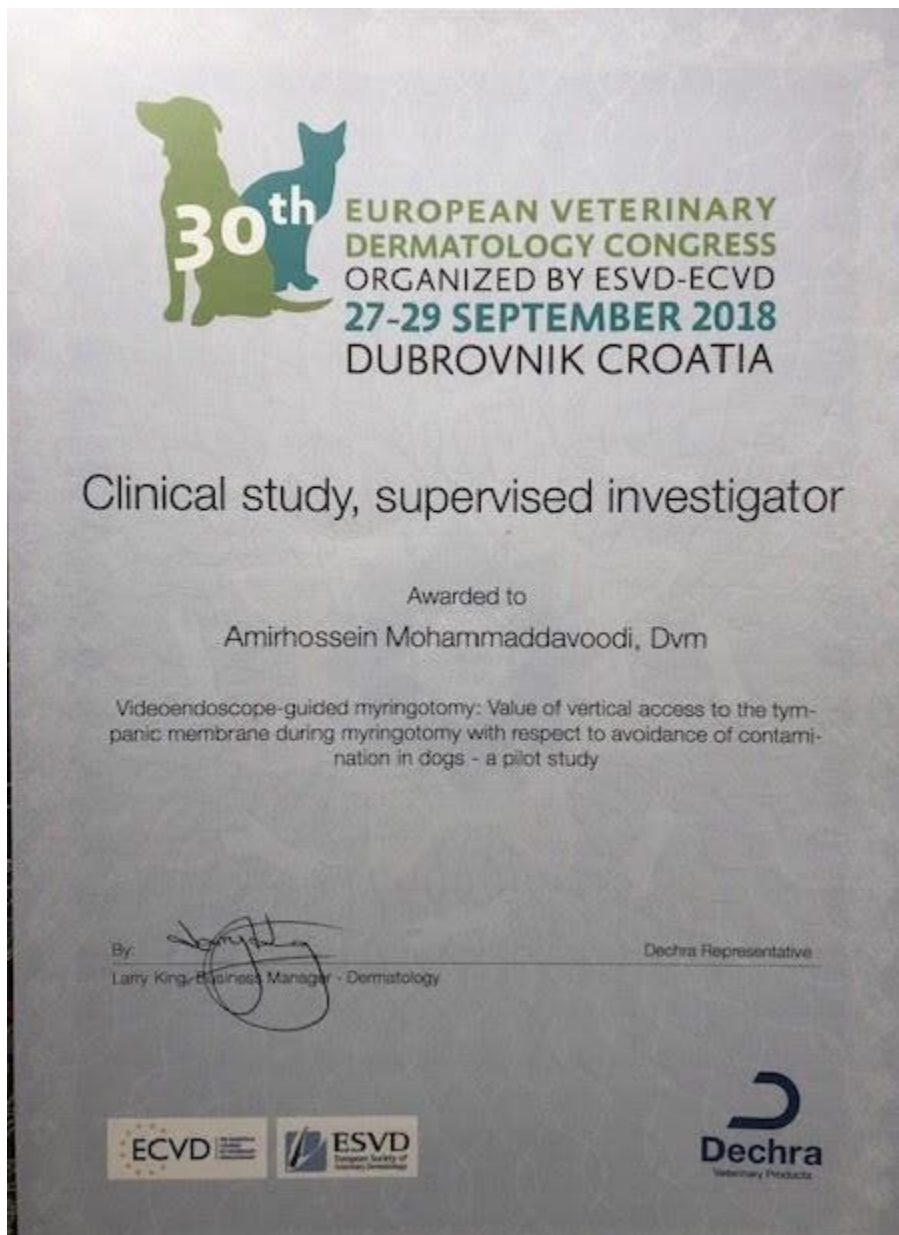## References

- Belmudes, A., Pressanti, C., Barthez, P. Y., Castilla-Castaño, E., Fabries, L., & Cadiergues, M. C. (2018). Computed tomographic findings in 205 dogs with clinical signs compatible with middle ear disease: A retrospective study. *Veterinary Dermatology*, 29, 45-e20.
- Bruyette, D. S., & Lorenz, M. D. (1993). Otitis externa and otitis media: Diagnostic and medical aspects. *Seminars in veterinary medicine and surgery (small animal)*, 8, 3-9.
- Classen, J., Bruehshwein, A., Meyer-Lindenberg, A., & Mudler, R. S. (2016). Comparison of ultrasound imaging and video otoscopy with cross-sectional imaging for the diagnosis of canine otitis media. *The Veterinary Journal*, 217, 68-71.
- Cole, L. K., Kwochka, K. W., Kowalski, J. J., & Hillier, A. (1998). Microbial flora and antimicrobial susceptibility patterns of isolated pathogens from the horizontal ear canal and middle ear in dogs with otitis media. *Journal of the American Veterinary Medical Association*, 212, 534-538.
- Cole, L. K., Kwochka, K. W., Podell, M., Hillier, A., & Smeak, D. D. (2002). Evaluation of radiography, otoscopy, pneumotoscopy, impedance audiometry and endoscopy for the diagnosis of otitis media. Vol. Eds. K. L. Thoday, C. S. Foil, & R. Bon (Eds.), *Evaluation of radiography, otoscopy, pneumotoscopy, impedance audiometry and endoscopy for the diagnosis of otitis media. Advances in veterinary dermatology*, 4, 49-55.
- Cole, L. K., Samii, V. F., Wagner, S. O., & Rajala-Schultz, P. J. (2015). Diagnosis of primary secretory otitis media in the cavalier King Charles spaniel. *Veterinary Dermatology*, 26, 459-e107.
- Daodu, O. B., Amosun, E. A., & Oluwayelu, D. O. (2017). Antibiotic resistance profiling and microbiota of the upper respiratory tract of apparently healthy dogs in Ibadan, south west Nigeria. *African Journal of Infectious Diseases*, 11, 1-11.
- Diekie, A. M., Doust, R., Cromarty, L., Johnson, V. S., Sullivan, M., & Boyd, J. S. (2003). Comparison of ultrasonography, radiography and a single computed tomography slice for the identification of fluid within the canine tympanic bulla. *Research in Veterinary Science*, 75, 209-216.
- Doyle, R. S., Skelly, C., & Bellenger, C. R. (2004). Surgical management of 43 cases of chronic otitis externa in the dog. *Irish Veterinary Journal*, 57, 22-30.
- Fraser, G., Gregor, W. W., Mackenzie, C. P., Spreull, J. S. A., & Withers, A. R. (1969). Canine ear disease. *Journal of Small Animal Practice*, 10, 725-754.
- Garosi, L. S., Dennis, R., & Schwarz, T. (2003). Review of diagnostic imaging of ear diseases in the dog and cat. *Veterinary Radiology and Ultrasound*, 44, 137-146.

- Griffin, C. E. (2006). Otitis techniques to improve practice. *Clinical Techniques in Small Animal Practice*, 21, 96–105.
- Griffin, C. E. (2010). Classifying cases of otitis externa the PPSP System. In *Proceedings of ESVD Workshop on Otitis*.
- Holt, D. E., & Walker, L. (1997). Radiographic appearance of the middle ear after ventral bulla osteotomy in five dogs with otitis media. *Veterinary Radiology & Ultrasound*, 38, 182–184.
- Krahwinkel, D. J., Pardo, A. D., Sims, M. H., & Bubb, W. J. (1993). Effect of total ablation of the external acoustic meatus and bulla osteotomy on auditory function in dogs. *Journal of the American Veterinary Medical Association*, 202, 949–952.
- Lane, J. G., & Little, C. J. L. (1986). Surgery of the canine external auditory meatus: A review of failures. *Journal of Small Animal Practice*, 27, 247–254.
- Little, C. J., & Lane, J. G. (1989). An evaluation of tympanometry, otoscopy and palpation for assessment of the canine tympanic membrane. *The Veterinary Record*, 124, 5–8.
- Logas, D. B. (1994). Diseases of the ear canal. *Veterinary Clinics of North America: Small Animal Practice*, 24, 905–919.
- Mastuda, H., Tojo, M., Fukui, K., Imori, T., & Baba, E. (1984). The aerobic bacterial flora of the middle and external ears in normal dogs. *Journal of Small Animal Practice*, 25, 269–274.
- Miller, W. H., Griffin, C. E., & Campbell, K. L. (2013). Diseases of eyelids, claws, anal sacs, and ears. *Müller & Kirk's small animal dermatology* (7th eds, pp. 724–773). St. Louis: Elsevier Inc.
- Nuttall, T. (2016). Successful management of otitis externa. *In Practice*, 38(Suppl 2), 17–21.
- Owen, M. C., Lamb, C. R., Lu, D., & Targett, M. P. (2004). Material in the middle ear of dogs having magnetic resonance imaging for investigation of neurologic signs. *Veterinary Radiology & Ultrasound*, 45, 149–155.
- Palmeiro, B. S., Morris, D. O., Wiemelt, S. P., & Shofer, F. S. (2004). Evaluation of outcome of otitis media after lavage of the tympanic bulla and long-term antimicrobial drug treatment in dogs: 44 cases (1998–2002). *Journal of the American Veterinary Medical Association*, 225, 548–553.
- Paterson, S. (2016). Discovering the causes of otitis externa. *In Practice*, 38(Suppl 2), 7–11.
- Paterson, S. (2018). Otitis media with effusion in the boxer: A report of seven cases. *Journal of Small Animal Practice*, 59, 646–650.
- Reinbacher, E., Kneissl, S., Hirt, R., Spengler, J., & Panakova, L. (2020). Myringotomy in dogs: Contamination rate from the external ear canal—a pilot study. *Veterinary and Animal Science*, 10, Article 100125.
- Rose, W. R. (1977). Small animal clinical otology. Surgery 1-myringotomy. Number twenty-two in a series. *Veterinary Medicine, Small Animal Clinician: Veterinary Medicine, Small Animal Clinician*, 72, 1646–1650.
- Rosychuk, R.A.W., & Bloom, P. (2010). Otitis media: How common and how important. In D. J. DeBoer, V. K. Affolter, & P. B. Hill (Vol. Eds), (Eds.). *Advances in veterinary dermatology*, Volume 6, (pp. 345–353). Oxford, UK: Wiley-Blackwell.
- Schick, A. E., Angus, J. C., & Coyner, K. S. (2007). Variability of laboratory identification and antibiotic susceptibility reporting of *Pseudomonas* spp. isolates from dogs with chronic otitis externa. *Veterinary Dermatology*, 18, 120–126.
- Shell, L. G. (1988). Otitis media and otitis interna: Etiology, diagnosis, and medical management. *Veterinary Clinics of North America Small Animal Practice*, 18, 885–899.
- Spreull, J. S. A. (1964). Treatment of otitis media in the dog. *Journal of Small Animal Practice*, 5, 107–122.
- Strain, G. M., & Fernandes, A. J. (2015). Handheld tympanometer measurements in conscious dogs for the evaluation of the middle ear and auditory tube. *Veterinary Dermatology*, 26, 193–e40.



### 3 Award



## 4 Summary

### 4.1 Summary

Myringotomy is a minimally invasive method for diagnosing and treating otitis media in dogs having an intact tympanic membrane. In a recent study, the contamination rate of middle ear aspirates from the external ear canal via myringotomy was over 67%. The objective of this study was to evaluate the impact of gravity on the contamination rate of the middle ear aspirates by the material from external ear canal, during the video-otoscopically guided myringotomy with the vertical access to the tympanic membrane, with the person performing the procedure positioned underneath the dog.

Thirty-six ears ( $n = 36$ ) from 20 canine fresh cadavers without evidence of otitis externa and otitis media based on a CT scan and otoscopy were included. The ear canals were video-otoscopically flushed with a sterile saline in conventional manner (the ear upside on the normal examination table). Instillation of the diluted fluorescent dye into the ear canal and immediate retrieval were performed. After that, the patient was positioned on a custom-made fenestrated table plate and the performer took a position beneath the dog. A novel modified video-otoscopically guided myringotomy approaching the caudoventral part of the tympanum vertically from underneath was performed. Contamination rates were assessed by the visual detection of fluorescent dye within the aspirated fluid, either by yellow staining solely, or a positive fluorescence test. Cytology and microbial culture from external ear canals and middle ear aspirates were accomplished in all included ears. Middle ear sample contamination by material from the ear canal was identified in 2 of 36 (5.6%) ears. Neither a change in colour nor fluorescence was detected in 34 of 36 (94.4%) middle ear samples. Sixteen of 36 (44.44%) external ear canal samples and 4 of 36 (11.1%) middle ear aspirates had a positive bacterial culture. This novel technique is a promising method for the

middle ear material collection in patients with concurrent otitis externa, even though the procedure needs to be performed on the special table. Protective working clothes and eyeglasses as well as training of this technique seem to be mandatory.

## **4.2 Zusammenfassung**

Die Myringotomie ist eine minimalinvasive Methode und wird zur Diagnose und Behandlung der Otitis media bei Hunden mit intaktem Trommelfell genutzt. In einer kürzlich publizierten Studie lag die Kontaminationsrate von Mittelohraspiraten mit dem Material aus den Gehörgängen mittels Myringotomie bei über 67%. Das Ziel dieser Studie war es, den Einfluss der Schwerkraft auf die Kontaminationsrate von Mittelohraspiraten durch Material aus dem Gehörgang während der video-otoskopisch geführten Myringotomie mit vertikalem Zugang zum Trommelfell zu bewerten, wobei die untersuchende Person unterhalb des Tierkörpers positioniert ist.

Es wurden insgesamt 36 Ohren von 20 frischen Hundekadavern, basierend auf CT- und otoskopischer Untersuchung frei von Otitis externa und media, eingeschlossen. Die Ohren wurden auf einem normalen Untersuchungstisch mit dem zu untersuchenden Ohr nach oben video-otoskopisch mit steriler Kochsalzlösung gespült. Verdünnte fluoreszierende Flüssigkeit wurde in den Gehörgang instilliert und sofort wieder abgesaugt. Danach wurde der Patient auf einen speziell gestalteten hohen Tisch mit fenestrierter Tischplatte gelegt, so dass der Untersucher von unterhalb dieses Tisches durch das Fenster den Zugang zum Patientenkopf hatte. Eine neuartige modifizierte video-otoskopisch geführte Myringotomie mit vertikaler Annäherung zum kaudoventralen Teil des Tympanums wurde durchgeführt. Die Kontaminationsrate wurde durch visuellen Nachweis von gelber, fluoreszierender Flüssigkeit in dem abgesaugten Material entweder durch alleinige Gelbfärbung oder durch einen positiven Fluoreszenztest bewertet. Zytologische und mikrobielle

Untersuchungen sowohl aus den Gehörgängen als auch aus den Mittelohraspiraten wurden bei allen in der Studie inkludierten Ohren durchgeführt. Bei 2 von 36 (5,5%) Ohren wurde eine Kontamination der Mittelohrprobe durch das Material aus dem Gehörgang festgestellt. In 16 von 36 (44,4%) gesammelten Proben von Gehörgängen und 4 von 36 (11,1%) von Mittelohraspiraten konnte bakterielles Wachstum nachgewiesen werden.

Diese neue Technik ist eine vielversprechende Methode zur Sammlung von Mittelohrmaterial bei Patienten mit gleichzeitiger Otitis externa, obwohl ein speziell angefertigter Arbeitstisch, Schutzbrille und Bekleidung sowie vorhergehendes Training dieser Technik notwendig sind.



### **4.3 Abbreviations**

**OE:** Otitis externa

**EEC:** External ear canal

**TM:** Tympanic membrane

**OM:** Otitis media

**PSOM:** Primary secretory otitis media

**CKCS:** Cavalier King Charles Spaniel

**MEC:** Middle ear cavity

**OI:** Otitis interna

**VO:** Video-otoscopy

**CT:** Computed tomography

**MRI:** Magnetic resonance imaging

**CAD:** Cadaver

## 5 Bibliography

Belmudes, A., Pressanti, C., Barthez, P. Y., Castilla-Castaño, E., Fabries, L., & Cadiergues, M. C. (2018) Computed tomographic findings in 205 dogs with clinical signs compatible with middle ear disease: a retrospective study. *Veterinary Dermatology*, 29: 45-e20.

Bruyette, D. S., & Lorenz, M. D. (1993) Otitis externa and Otitis media: diagnostic and medical aspects. *Seminars in Veterinary Medicine and Surgery (Small Animal)*, 8: 3-9.

Classen J, Bruehschwein A, Meyer-Lindenberg A, Mueller RS. (2016) Comparison of ultrasound imaging and video otoscopy with cross-sectional imaging for the diagnosis of canine otitis media. *The Veterinary Journal*, 217: 68–71.

Cole, L. K., Kwochka, K. W., Kowalski, J. J., & Hillier, A. (1998) Microbial flora and antimicrobial susceptibility patterns of isolated pathogens from the horizontal ear canal and middle ear in dogs with OM. *Journal of the American Veterinary Medical Association* 212: 534-538.

Cole, L. K., Kwochka, K. W., Podell, M., Hillier, A., & Smeak, D. D. (2002) Evaluation of radiography, otoscopy, pneumotoscopy, impedance audiometry and endoscopy for the diagnosis of otitis media. *Advances in Veterinary Dermatology*, 4: 49-55.

Cole, L. K., Samii, V. F., Wagner, S., & Rajala-schultz, P. J. (2011) Diagnosis of primary secretory otitis media in the Cavalier King Charles spaniel. *Veterinary Dermatology*, 22: 297

Cole, L. K. (2012) Primary secretory otitis media in Cavalier King Charles spaniels. *Veterinary Clinics of North America: Small Animal Practice*, 42: 1137-1142.

Dickie, A. M., Doust, R., Cromarty, L., Johnson, V. S., Sullivan, M., & Boyd, J. S. (2003) Comparison of ultrasonography, radiography and a single computed tomography slice for the identification of fluid within the canine tympanic bulla. *Research in Veterinary Science*, 75: 209-216.

Fraser G, Gregor WW, Mackenzie CP, Spreull JSA, Withers AR. (1969) Canine Ear Disease. *Journal of Small Animal Practice*, 10: 725–754.

Griffin, C. E. (2006) Otitis techniques to improve practice. *Clinical Techniques in Small Animal Practice*, 21: 96-105.

Garosi, L.S., Dennis, R. and Schwarz, T. (2003) Review of diagnostic imaging of ear diseases in the dog and cat. *Veterinary Radiology & Ultrasound*, 44: 137-146

Griffin, C. E. (2010) Classifying cases of otitis externa the PPSP System. In *Proceedings of ESVD Workshop on Otitis*. St Helens.

Lane, J.G. and Little, C.J.L. (1986) Surgery of the canine external auditory meatus: a review of failures. *Journal of Small Animal Practice*, 27: 247-254.

Logas DB. (1994) Diseases of the ear canal. *Veterinary Clinics of North America: Small Animal Practice*, 24: 905–919.

Owen, M. C., Lamb, C. R., Lu, D., & Targett, M. P. (2004) Material in the middle ear of dogs having magnetic resonance imaging for investigation of neurologic signs. *Veterinary Radiology & Ultrasound*, 45: 149-155.

Paterson, S. (2018) Brainstem auditory evoked responses in 37 dogs with otitis media before and after topical therapy. *Journal of Small Animal Practice*, 59: 10-15.

Rose, W. R. (1977) Small animal clinical otology. Surgery 1-myringotomy. Number twenty-two in a series. *Veterinary Medicine Small Animal Clinician*, 72: 1646.

Shell, L.G. (1988) Otitis media and otitis interna: etiology, diagnosis, and medical management. *Veterinary Clinics of North America: Small Animal Practice*, 18: 885-899.

Stern-Sertholtz, W., Sjöström, L., & Hårkanson, N. W. (2003) Primary secretory OM in the Cavalier King Charles spaniel: a review of 61 cases. *Journal of Small Animal Practice*, 44: 253-256.